

Otolaryngology -- Head and Neck Surgery

<http://oto.sagepub.com/>

Sac-Vein Decompression for Intractable Meniere's Disease: Two-Year Treatment Results

Gerard J. Gianoli, Michael J. Larouere, Jack M. Kartush and John Wayman

Otolaryngology -- Head and Neck Surgery 1998 118: 22

DOI: 10.1016/S0194-5998(98)70370-5

The online version of this article can be found at:

<http://oto.sagepub.com/content/118/1/22>

Published by:



<http://www.sagepublications.com>

On behalf of:



AMERICAN ACADEMY OF
OTOLARYNGOLOGY-
HEAD AND NECK SURGERY

FOUNDATION

[American Academy of Otolaryngology- Head and Neck Surgery](http://www.aao-hn.org)

Additional services and information for *Otolaryngology -- Head and Neck Surgery* can be found at:

Email Alerts: <http://oto.sagepub.com/cgi/alerts>

Subscriptions: <http://oto.sagepub.com/subscriptions>

Reprints: <http://www.sagepub.com/journalsReprints.nav>

Permissions: <http://www.sagepub.com/journalsPermissions.nav>

>> [Version of Record](#) - Jan 1, 1998

[What is This?](#)

Sac-vein decompression for intractable Meniere's disease: Two-year treatment results

GERARD J. GIANOLI, MD, MICHAEL J. LAROUERE, MD, JACK M. KARTUSH, MD, and JOHN WAYMAN, MD,
New Orleans, Louisiana, Farmington Hills, Michigan, and Rochester, New York

Surgical intervention has been offered to patients with Meniere's disease who have failed medical treatment and have disabling symptoms. Surgical options have included labyrinthectomy (mechanical and chemical), vestibular neurectomy, and endolymphatic sac surgery with or without shunting. We present a modification of endolymphatic sac decompression surgery that includes wide decompression of the sigmoid sinus, posterior cranial fossa dura, and endolymphatic sac (sac-vein decompression). Thirty-five patients underwent 37 primary procedures with 2 years of follow-up. Patients were evaluated according to the 1985 American Academy of Otolaryngology-Head and Neck Surgery criteria for assessing Meniere's disease. Vestibular symptom severity was resolved or mild in 92% and disability severity was none or mild in 95% of patients at 2 years after surgery. Vertigo control was complete or substantial in 85% and 100% of patients at 1 and 2 years after surgery. Audiologic data showed stable or improved hearing in 86% and 85% of patients at 1 and 2 years after surgery. In summary, wide decompression of the sigmoid sinus, posterior cranial fossa dura, and endolymphatic sac offers improved control of vertigo and hearing stabilization for intractable Meniere's disease compared with simple endolymphatic sac decompression or shunt surgery. (Otolaryngol Head Neck Surg 1998;118:22-9.)

The treatment of patients with Meniere's disease remains controversial. Current philosophy dictates medical management of symptoms with a variety of treatments. These have included dietary alterations, diuretics, allergy control, steroid therapy, and others. Only when symptoms from Meniere's disease remain refractory to medical control are surgical alternatives explored. Surgical options have included labyrinthectomy (mechanical and chemical), vestibular neurectomy, and endolymphatic sac surgery with or without shunting.

Endolymphatic sac surgery has been performed with insertion of a variety of prostheses including simple silicone sheets, tubing, and unidirectional valves directing endolymph flow to either the mastoid or subarachnoid space: endolymphatic sac/shunt surgery.¹ Endolymphatic sac surgery has been performed without shunt or

valve insertion: endolymphatic sac decompression.² A variation of endolymphatic sac decompression surgery has also been presented that includes wide decompression of the posterior cranial fossa dura surrounding the endolymphatic sac.³

Several studies analyzing the temporal bone anatomy in Meniere's disease have found consistent alterations in the arrangement of the sigmoid sinus and Trautman's triangle.⁴ Most patients with Meniere's disease will have anterior and medial displacement of the sigmoid sinus and a generalized decreased pneumatization of the mastoid. This condition reduces the size of Trautman's triangle and often places the sinus in direct contact with the endolymphatic sac. We have noted this anatomic arrangement in our clinical practice. Because of this anatomic alteration we would often remove the bone from the sigmoid sinus and posterior cranial fossa to afford improved visualization of the endolymphatic sac. From retrospective review one of us (J.M.K.) observed improved benefit when the sigmoid sinus was included in the decompression and particularly when the sigmoid sinus was anteriorly and medially displaced. Consequently, we have altered our surgical technique to include decompression of the sigmoid sinus.⁵

We now present results from our modification of endolymphatic sac decompression surgery, which includes wide decompression of the sigmoid sinus, posterior cranial fossa dura, and endolymphatic sac (sac-

From the Department of Otolaryngology-Head and Neck Surgery (Dr. Gianoli), Tulane University Medical Center, New Orleans; Michigan Ear Institute (Drs. LaRouere and Kartush), Farmington Hills; and the Department of Otolaryngology-Head and Neck Surgery (Dr. Wayman), University of Rochester Medical Center.

Reprint requests: Gerard J. Gianoli, MD, Department of Otolaryngology-HNS, Tulane University Medical Center, 1430 Tulane Ave., New Orleans, LA 70112.

Copyright © 1998 by the American Academy of Otolaryngology-Head and Neck Surgery Foundation, Inc.

0194-5998/98/\$5.00 + 0 23/1/76738

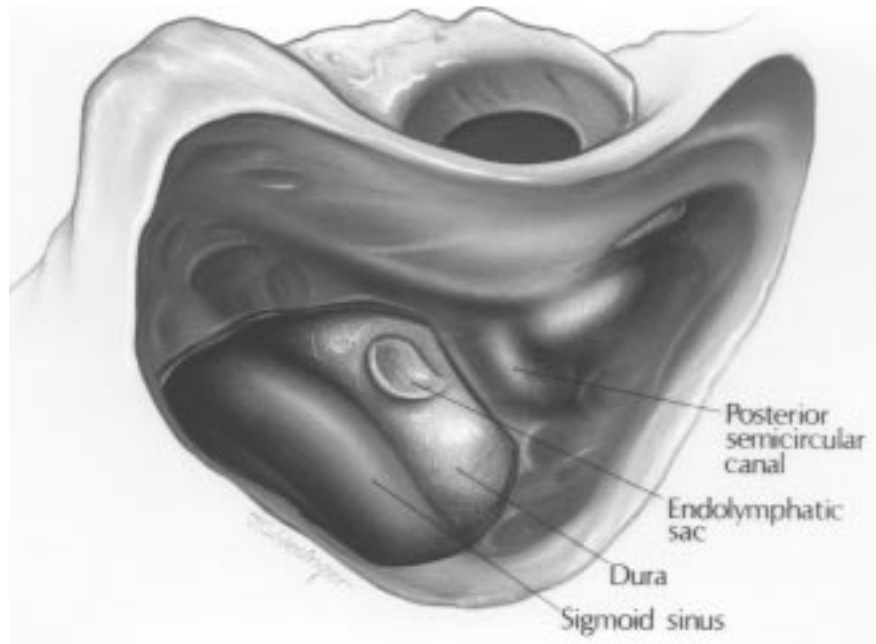


Fig. 1. Wide decompression of bone over sigmoid sinus, posterior fossa dura, and endolymphatic sac. Additional bone is removed over jugular bulb, if endolymphatic sac is in contact with this structure.

vein decompression). The patients in this study are part of an ongoing prospective evaluation of this surgical modification of endolymphatic sac decompression.

METHODS AND MATERIAL

Patients were selected for inclusion in this study on a prospective basis from 1990 to 1992. Patients with classic Meniere's disease who were refractory to medical treatment were offered surgical intervention. Retrosigmoid vestibular neurectomy and sac-vein decompression were both offered to patients failing medical treatment. This study represents the 2-year follow-up of patients who chose decompression surgery.

The clinical criteria used to define Meniere's disease for inclusion in this study included the unilateral symptoms of fluctuating hearing loss, aural pressure, episodic vertigo, and tinnitus. The fluctuating hearing loss was a flat or low-frequency sensorineural type. The vertigo was abrupt in onset, usually lasted a few hours, was rotational in nature, and was often associated with nausea. Patients with atypical Meniere's disease such as cochlear hydrops or vestibular hydrops were excluded from the study. Patients with bilateral Meniere's disease were included if each ear presented with symptoms at discretely separate time frames and both displayed classic Meniere's symptoms.

All patients with the clinical diagnosis of Meniere's disease were routinely screened for underlying causes

by magnetic resonance imaging scan and metabolic evaluations. Magnetic resonance imaging scanning of the eighth cranial nerves and brain was routinely performed with gadolinium enhancement. Audiometry and electronystagmography were routinely performed on all patients. Metabolic evaluation included thyroid function studies, fluorescent treponemal antibody testing, serum chemistries, complete blood count, cholesterol/triglyceride screen, creatinine, glucose, and antinuclear antibody testing. Additional evaluations were performed as warranted by the individual patient history. Any patient who had an identifiable underlying cause for his or her symptoms was excluded from the study. Any patient who had undergone any previous otologic surgery was excluded from the study.

Patients were evaluated before surgery and for 2 years after surgery with the 1985 American Academy of Otolaryngology-Head and Neck Surgery reporting criteria for Meniere's disease.⁶ This evaluation included audiometric assessment, physician evaluation, and patient self-assessment with standardized questionnaires. Any patient not completing the self-assessment questionnaire was contacted by telephone for completion of the questionnaire. Audiometric evaluation was performed at least annually to assess both 1- and 2-year status. Audiometric parameters used for comparison were pure tone averages at 500 Hz, 1 kHz, and 2 kHz (3 kHz was seldom performed) and speech discrimination.

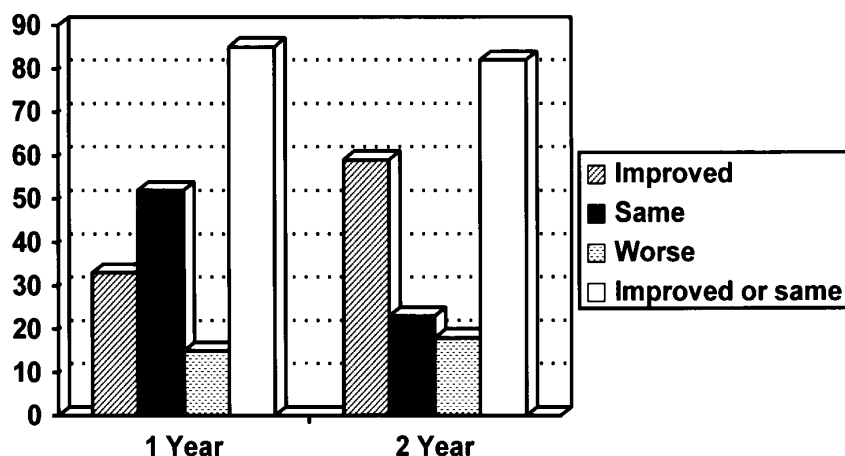


Fig. 2. Hearing results.

The preoperative hearing was defined as the poorest hearing level in the 6 months preceding surgery. The 1-year postoperative hearing was defined as the poorest hearing level from 6 to 12 months after surgery, and the 2-year postoperative hearing result was defined as the poorest hearing level from 18 to 24 months after surgery. This patient population represents an ongoing study for which we hope to report further long-term results for sac-vein decompression.

Surgical Technique. With the patient under general anesthesia, wide mastoidectomy is performed in the routine fashion. The sigmoid sinus and posterior cranial fossa anterior to the sinus are skeletonized. With diamond burs and gentle dissection, the overlying bone is then removed. Often the sigmoid sinus is superficially cauterized with bipolar electrocautery at a very low current setting. This procedure will result in shrinkage of the vein (approximately 15% to 25%) and improve visualization of the posterior fossa dura and endolymphatic sac. Removal of bone from the posterior fossa dura is accomplished superiorly from just below the sinodural angle to inferiorly at the jugular bulb and from posteriorly at the sigmoid sinus to anteriorly at labyrinthine bone. This wide decompression allows complete exposure of the endolymphatic sac and contiguous dura superiorly, posteriorly, and inferiorly (Fig. 1). Bone removal over the jugular bulb is performed if the endolymphatic sac is found to be in continuity with the bulb. Silicone sheeting is typically placed over the exposed dura to prevent adhesions to overlying soft tissue.

RESULTS

Thirty-five patients who underwent 37 surgeries were included for evaluation, and follow-up was com-

plete in all patients included in the study. The average age at the time of surgery was 53 years and ranged from 29 to 80 years. The average duration of symptoms before surgery was approximately 4¹/₂ years. The left ear was involved in 18 cases, the right ear in 9 cases, and bilateral Meniere's disease was found in 10 cases. Surgery was performed on 20 left ears and 17 right ears.

Audiometric evaluation revealed no significant change for the average pure tone average or speech discrimination at 1- and 2-year follow-up. Average pure tone average was 42 dB before surgery, 37 dB at the 1-year evaluation, and 42 dB at the 2-year evaluation. Speech discrimination was 78% before surgery, 81% at the 1-year evaluation, and 75% at the 2-year evaluation. This result is in contrast, however, to individual audiometric evaluations that demonstrated improved or stable hearing in 86% and 82% of patients at 1 and 2 years, respectively. Figure 2 details audiometric data as defined by the 1985 American Academy of Otolaryngology-Head and Neck Surgery criteria.

Vestibular data for disability severity and symptom severity according to physician assessment at the 2-year follow-up are delineated in Figs. 3 and 4. Overall, physician examiners believed that 92% of the patients in the study were improved and that 8% were unchanged compared with preoperative severity of symptoms and disability. No patient in the study was believed to have worsening of symptoms or disability compared with preoperative status.

Figures. 5 and 6 detail patient assessment of vertigo control and overall result at 1 and 2 years after surgery. Although all patients had complete or substantial control of vertigo at the 2-year follow-up, several reported "unchanged" (12%) and "worse" (6%) regarding overall

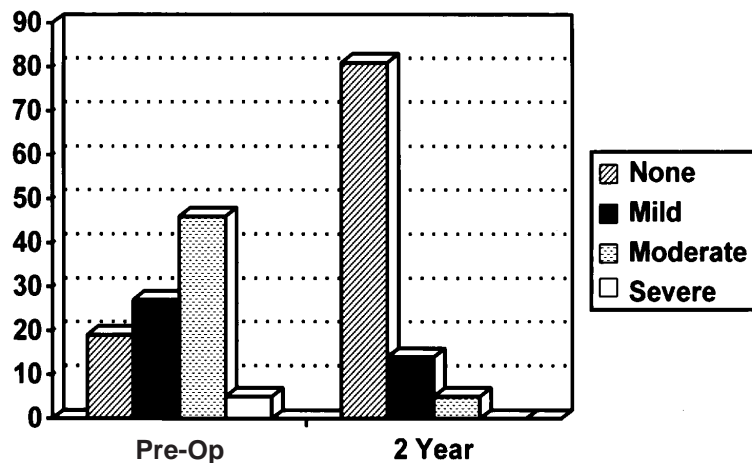


Fig. 3. Physician assessment of disability severity.

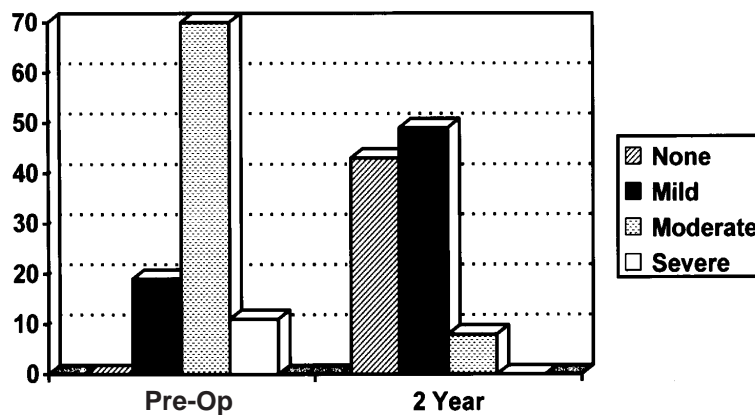


Fig. 4. Physician assessment of symptom severity.

result. These patients noted several difficulties other than vertigo. A few noted that although vertigo was controlled, they had a chronic light-headed feeling. Some reported an overall “worse” result because of continued nonvestibular symptoms such as aural fullness, hearing loss, and tinnitus.

All but one of the patients who expressed dissatisfaction (either from the standpoint of balance or hearing) with the results from their sac-vein decompression had bilateral Meniere’s disease. Only one patient in this series went on to have a vestibular neurectomy for definitive control of vertigo. This patient had a preoperative pure tone average of 48 dB, a 1-year pure tone average of 47 dB, and a 2-year pure tone average of 13 dB. Vertigo was improved but not eliminated in this patient, and he subsequently elected to undergo vestibular nerve section. One patient with bilateral Meniere’s had one ear completely controlled with sac-vein decompression, and the contralateral ear, although

improved after the sac-vein decompression, has required intratympanic gentamycin through a ventilation tube, which is currently controlling her symptoms.

DISCUSSION

Current treatment for patients with Meniere’s disease has typically relied on diuretics and a low salt diet. Vertiginous episodes are treated symptomatically with vestibular suppressants and antiemetics. On empiric evaluation it appears that medical management is successful for most patients with Meniere’s disease, but currently no controlled trials support the effectiveness of medical management. Surgical treatment has been reserved for the most symptomatic cases that have failed to benefit from medical therapy. The most common surgical interventions used include endolymphatic sac surgery, labyrinthectomy, and vestibular neurectomy.

Vestibular neurectomy and labyrinthectomy result in

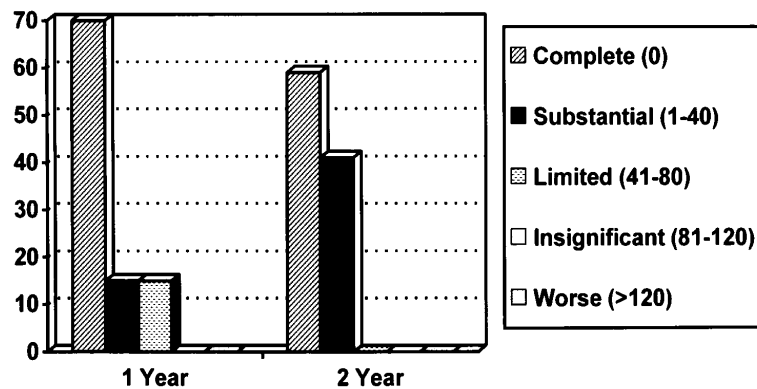


Fig. 5. Patient assessment of vertigo control.

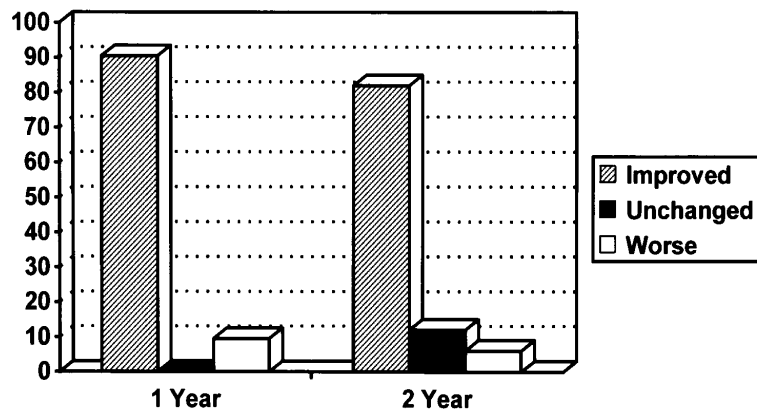


Fig. 6. Patient assessment of overall results.

complete unilateral deafferentation of the affected vestibular system. The control of episodic vertigo has been excellent, with 85% to 99% of patients reporting complete control of vertigo.^{7,8} Total unilateral vestibular deafferentation has been shown to result in significantly better control of vertigo compared with nonsurgical treatment and endolymphatic sac surgery.⁹ Unfortunately, labyrinthectomy also results in sensorineural deafness and is reserved for patients with no useful hearing in the affected ear. In addition, 15% to 25% of patients undergoing labyrinthectomy will have persistent postoperative disequilibrium.⁷ Vestibular neurectomy has the advantage of preserving hearing but also requires an intracranial procedure with its attendant potential risks and morbidity such as persistent headache from posterior fossa craniotomy. We have also witnessed postoperative disequilibrium in a significant percentage of our patients with vestibular neurec-

tomy. Another concern with procedures resulting in total unilateral vestibular deafferentation (i.e., vestibular neurectomy or labyrinthectomy) is the possible future development of Meniere's in the contralateral ear. This development occurs in 15% to 50% of patients and was seen in 29% of our patient population. Development of Meniere's disease in a patient who has undergone contralateral vestibular deafferentation presents a very difficult problem for the clinician. Chemical labyrinthectomy by several means has been advocated as an alternative to the previously mentioned procedures.^{10,11} These procedures result in varying degrees of reduction in unilateral vestibular function with varying results in hearing preservation, both dependent on the dose of aminoglycoside in use.

Results of endolymphatic sac surgery have varied from 33% to 94% success for control of vertigo, with most authors reporting success in the range of 70% to

80% with some decline in cure rates over time.^{12,13} Endolymphatic sac surgery has a very low morbidity and is generally performed on an outpatient basis. Bilateral endolymphatic sac surgery can be performed on patients with bilateral Meniere's disease without the concerns of bilateral vestibular deafferentation as would be produced by bilateral vestibular neurectomy. Revision endolymphatic sac surgery can be performed on patients with recurrent symptoms with similar success rates as primary procedures.¹⁴ Hearing improvement or stabilization has been touted as a potential benefit of endolymphatic sac surgery with varying results in the literature. Review of the literature demonstrates postoperative hearing improved or maintained at preoperative levels in 53% to 90% with a minimum of 1 year of follow-up.¹⁵

The reasons for such wide variations for success in endolymphatic sac surgery include differing criteria to define success, various lengths of follow-up, differing patient populations (classic vs atypical Meniere's), and differing surgical techniques. We have included only patients with classic idiopathic Meniere's disease, have used one standard technique, and have adhered to the 1985 American Academy of Otolaryngology-Head and Neck Surgery criteria for reporting in our study to try to eliminate some of these reporting problems.

Endolymphatic sac surgery has been very controversial. In 1981 Thomsen, et al.¹⁶ reported their results of a double-blind placebo-controlled trial comparing the effects of endolymphatic shunt surgery with those of simple mastoidectomy ("sham" surgery). They concluded that there was no difference in the effects of endolymphatic sac surgery and "sham" surgery. In addition, they concluded that there was a strong placebo effect when patients with Meniere's disease were treated. Although this study has raised questions about the efficacy of endolymphatic sac surgery, a reanalysis of the data by Pillsbury et al.¹⁷ with 1972 academy guidelines found that 87% of the patients treated with endolymphatic sac surgery had a successful outcome compared with 47% in the placebo group. They pointed out several statistical and experimental design flaws in the study by Thomsen et al.¹⁶ that make it difficult to accept the conclusion that endolymphatic sac surgery is merely a placebo. Whittaker¹⁸ has criticized the choice of mastoidectomy as a placebo in the Thomsen article. He has voiced the concern that mastoidectomy is more than a placebo, because it would lead to changes in the blood supply, local inflammatory effects, and subsequent effects to the inner ear. Smith and Pillsbury¹² have also pointed out that some of the patients undergoing "sham" surgery could have had perilymphatic fistulas that were sealed by the blood of the mastoidecto-

my. It is also interesting to note that despite the results of their study, the Danish group continues to use endolymphatic sac surgery as their procedure of choice for patients with Meniere's disease who fail medical therapy (Bretlau, personal communication, 1992).

In 1989 Glasscock et al.¹⁹ reviewed their experience with endolymphatic shunt surgery. They reported complete control of vertigo in 65% of patients at 3 years and 50% at 10 years. In addition, 60% noted hearing improvement and 71% were "very pleased" with the results of their surgery. They have abandoned sac surgery in favor of vestibular nerve section because of the higher rate of complete control of vertigo. Unfortunately, Glasscock et al.²⁰ did not state how many of their patients who had endolymphatic sac surgery had substantial, limited, insignificant, or poorer control of vertigo. They also did not state how many of their patients required additional surgery for control of their symptoms. (With nearly three fourths of their patients "very pleased" with the outcome from endolymphatic sac surgery, one would suppose that less than one fourth would require additional procedures.) They further state that "Morbidity with the retrosigmoid (vestibular neurectomy) procedures has been the same for sac operations." This does not seem likely, because the incidence of spinal fluid leak, meningitis, intracranial hemorrhage, posterior fossa craniotomy headache, and other complications seen with posterior fossa surgery are virtually nonexistent with endolymphatic sac surgery.

We believe results for vertigo control in our patients who underwent sac-vein decompression compare very favorably with studies previously published on endolymphatic sac surgery. Of all the patients who underwent sac-vein decompression, only two (6%) patients required an additional procedure for more substantial control of their vertigo: one retrosigmoid vestibular neurectomy and one intratympanic gentamycin. Both of these patients believed their vertigo was significantly improved, although not completely controlled, by sac-vein decompression. If results of vertigo control follow a similar pattern of many other endolymphatic sac surgeries, we should expect to see some deterioration of our success rate with time. However, because of the natural history of Meniere's disease to spontaneously regress (30% to 71%) over several years' time, we suspect that most of these patients will never need a destructive procedure and that the sac-vein decompression will have given them immediate relief from their vertiginous symptoms as opposed to waiting for a natural regression. An additional benefit from this more conservative procedure is that no bridge has been burned in the case of bilateral

Meniere's disease. The one patient who is receiving intratympanic gentamycin has bilateral Meniere's disease and had undergone bilateral sac-vein decompression. The first symptomatic ear had been completely controlled by sac-vein decompression. The second symptomatic ear had significantly improved control of vertigo after sac-vein decompression but has required intratympanic gentamycin for more complete control. If total unilateral vestibular deafferentation (i.e., vestibular neurectomy or labyrinthectomy) had been done on the first symptomatic ear, that patient's problem would be much more difficult at this point.

One of the few studies that reports vertigo control as high as that in this study is by Paparella and Sajjadi.¹ On review of their surgical technique we find fairly wide decompression of the endolymphatic sac and posterior fossa including the sigmoid sinus. The major difference in our technique is slightly wider bony decompression and no shunt insertion. We believe that if such high success rates are attainable without a shunt and a shunt carries with it a 1% to 2% chance of profound sensorineural hearing loss, then there is no reason to place a shunt. One of the few studies that reports as high a rate of hearing preservation or improvement is by Graham and Kemink.³ The technique they describe is similar to the one described here with wide decompression of the endolymphatic sac and entire posterior fossa dura posterior to the labyrinth, anterior to the sigmoid sinus, and between the sinodural angle and jugular bulb. The major difference in the technique described here is the addition of wide sigmoid sinus decompression and occasional jugular bulb decompression. The commonality of wide decompression of the endolymphatic sac and surrounding structures (posterior fossa dura and sigmoid sinus) as stressed in our procedure and in the two articles detailed previously is not described by authors who report much lower success rates. The typical technique reported is a decompression limited to where the surgeon believes the endolymphatic sac is located. We believe this type of approach makes visualization and localization of the endolymphatic sac more difficult. In addition, wide decompression of all the surrounding structures most likely allows further pressure equilibration and endolymph diffusion compared with a more limited decompression.

We would like to make the point that this study has included only patients with classic Meniere's disease. We and several other authors have noted a lower success rate in treating patients with atypical Meniere's disease with endolymphatic sac surgery (i.e., vestibular hydrops, cochlear hydrops). The differing success among these patient populations may be attributable to obstructed versus unobstructed flow of endolymph within the

labyrinth as noted by Schuknecht and R  ther.²⁰ However, even with endolymphatic flow obstruction at some proximal intralabyrinthine site, one would still expect to see pressure changes inside the labyrinth from the decompressive surgery. After bone is removed from the lateral aspect of the endolymphatic sac, the pressure of the endolymphatic sac should change from intracranial pressure to mastoid pressure, which in patients with normal eustachian tube function is atmospheric pressure. This pressure differential should lead to an immediate change in intralabyrinthine pressure and greater diffusion of endolymph to the endolymphatic sac.

Our study group demonstrated some rather dramatic improvements in hearing immediately after the sac-vein decompression. The group as a whole demonstrated improved or stable hearing in 85% and 82% of patients at 1 and 2 years after surgery. This result compares favorably with the 53% to 69% improved or stable hearing reported in most reports analyzing hearing results after endolymphatic sac surgery.¹⁵ An additional advantage of decompressive surgery is the lowered risk of sensorineural hearing loss as a complication of surgery. Unlike shunt placement, which carries a 2% risk of hearing loss with its placement, sac-vein decompression will not result in hearing loss unless the posterior semicircular canal is violated and not recognized.

Endolymphatic sac surgery can fail for several reasons. A wrong diagnosis would obviously lead to ineffective therapy. The diagnosis of Meniere's disease can sometimes be given to conditions that can mimic its symptoms quite effectively (vascular loop compression syndrome, perilymphatic fistula, autoimmune inner ear disease, and others). Technical surgical factors could also adversely affect outcome. Because of the frequent occurrence of an anterior and medially displaced sigmoid sinus, there is restricted exposure of the endolymphatic sac. The endolymphatic sac can be difficult to identify at times, and we have been witness during revision surgery of patients who had "endolymphatic sac" surgery that was performed on posterior fossa dura distant from the true endolymphatic sac. Other authors have noted fibrosis and osseous closure over the surgical sites. One study of revision endolymphatic sac surgery by Huang and Lin¹⁴ found there was a need for "wider decompression to eliminate these problems." Our modification of endolymphatic sac decompression surgery offers wide exposure of all surrounding structures and ensures full decompression of the endolymphatic sac. Bone regrowth should also be less of a problem because of such wide decompression.

Several anomalous findings have been reported in temporal bones of patients with Meniere's disease.⁴ These anatomic aberrations have included hypodevel-

opment of the vestibular aqueduct, endolymphatic sac, periaqueductal air cells, and generalized mastoid hypocellularity. The sigmoid sinus has been noted by several authors to have an anterior and medial displacement in patients with Meniere's disease. During surgery for Meniere's disease the endolymphatic sac has been observed to be in close proximity to the sinus and in many cases to be actually abutting the sinus. Wide decompression of the sigmoid sinus as we have performed offers improved exposure of the endolymphatic sac and very likely results in decreased pressure transmission. This procedure will result in an improved pressure gradient across the endolymphatic sac and improved absorption or diffusion of endolymph.

We believe that all patients with Meniere's disease should be treated initially with medical therapy. Conservative measures should be exhausted before surgical intervention is contemplated. This approach is justified by both the high success rate of medical therapy and the high rate of spontaneous remission. When surgery is offered to the patients, they are given the option of retrosigmoid vestibular neurectomy or sac-vein decompression. If the patient chooses sac-vein decompression and later has recurrent disabling vertigo, then retrosigmoid vestibular neurectomy is offered to the patient. For the patient with bilateral Meniere's disease we are more hesitant to offer vestibular neurectomy. These patients are often reevaluated for underlying causes (in particular, allergy) and are offered contralateral sac-vein decompression for a singly symptomatic ear or intramuscular streptomycin titration therapy for bilaterally symptomatic ears.

CONCLUSIONS

A modification of endolymphatic sac decompression has been presented: sac-vein decompression. This procedure includes wide decompression of the sigmoid sinus (from sinodural angle to jugular bulb), posterior cranial fossa dura (bounded by sigmoid sinus posteriorly, labyrinthine bone anteriorly, jugular bulb inferiorly, and sinodural angle superiorly), and endolymphatic sac. No shunt is introduced.

Sac-vein decompression offers improved control of vertigo and stabilization of hearing compared with traditional endolymphatic sac decompression or shunt surgery while virtually eliminating the risk of iatrogenic hearing loss.

We propose that this method allows more accurate identification and more complete decompression of the

endolymphatic sac, which may allow for decreased endolymphatic pressure.

We anticipate further analysis of this group of patients after 5 years of follow-up.

REFERENCES

1. Paparella MM, Sajjadi H. Endolymphatic sac enhancement. *Otolaryngol Clin North Am* 1994;27:381-402.
2. Shambaugh GE, Clemis JD, Arenberg IK. Endolymphatic duct and sac in Meniere's disease. *Arch Otolaryngol* 1969;89:816-25.
3. Graham MD, Kemink JL. Surgical management of Meniere's disease with endolymphatic sac decompression by wide bony decompression of the posterior fossa dura: technique and results. *Laryngoscope* 1984;94:680-3.
4. Paparella MM, Sajjadi H, DaCosat SS, Yoon TH, Le CT. Significance of the lateral sinus and Trautmann's triangle in Meniere's disease. In: Nadol JB Jr, editor. *Second international symposium on Meniere's disease*. Amsterdam: Kugler & Ghedini Publications; 1989. p.139-46.
5. LaRouere ML, Seidman MD, Kartush JK. Medical and surgical treatment of vertigo. In: Jacobson JP, Newman CW, Kartush JM, editor. *Handbook of balance function testing*. St Louis: Mosby-Year Book, Inc; 1993. p.337-57.
6. Pearson BW, Brackmann DE. Committee on hearing and equilibrium guidelines for reporting treatment results in Meniere's disease. *Otolaryngol Head Neck Surg* 1985;93:579-81.
7. Graham MD, Goldsmith MM. Labyrinthectomy. *Otolaryngol Clin North Am* 1994;27:325-35.
8. Silverstein H, Willcox TO. Vestibular nerve section. *Otolaryngol Clin North Am* 1994;27:347-62.
9. Silverstein H, Smouha E, Jones R. Natural history vs surgery for Meniere's disease. *Otolaryngol Head Neck Surg* 1989;1:6-16.
10. Nedzelski JM, Schessel DA, Bryce GE, Pfeleiderer AG. Chemical labyrinthectomy: local application of gentamicin for the treatment of unilateral Meniere's disease. *Am J Otol* 1992;13:18-22.
11. Norris CH, Amedee RG, Risey JA, Shea JJ. Selective chemical vestibulectomy. *Am J Otol* 1990;6:395-400.
12. Smith WC, Pillsbury HC. Surgical treatment of Meniere's disease since Thomsen. *Am J Otol* 1988;9:39-43.
13. Morrison GA, O'Reilly BJ, Chevretton EB, Kenyon GS. Long-term results of revision endolymphatic sac surgery. *J Laryngol Otol* 1990;104:613-6.
14. Huang TS, Lin CC. Revision endolymphatic sac surgery for recurrent Meniere's disease. *Acta Otolaryngol* 1991;485 (Suppl):131-44.
15. Goin DW, Mischke RE, Esses BA, Young D, Priest EA, Whitmoyer-Goin V. Hearing results from endolymphatic sac surgery. *Trans Am Otol Soc Inc* 1991;79:189-43.
16. Thomsen J, Bretlau P, Tos M, Jonsen NJ. Placebo effect in surgery for Meniere's disease. *Arch Otolaryngol* 1981;107:271-7.
17. Pillsbury HC, Arenberg I, Ferraro J, Ackley R. Endolymphatic sac surgery: the Danish sham surgery study: an alternative analysis. *Otolaryngol Clin North Am* 1983;16:123-7.
18. Whittaker CK. Therapy for Meniere's disease (letter). *Arch Otolaryngol* 1981;107:775.
19. Glasscock ME, Jackson CG, Poe DS, Johnson GD. What I think of sac surgery in 1989. *Am J Otol* 1989;10:230-3.
20. Schuknecht HF, Rütther A. Blockage of longitudinal flow in endolymphatic hydrops. *Eur Arch Otorhinolaryngol* 1991; 248:209-17.