

## SUPERIOR SEMICIRCULAR CANAL DEHISCENCE: A NEW CAUSE OF VERTIGO

JENNIFER L. SMULLEN, MD; ERIC C. ANDRIST, BS; GERARD J. GIANOLI, MD

There are many known causes of vertigo, but many cases remain unexplained. Sound-induced, pressure-induced, or positional vertigo caused by bony dehiscence of the superior semicircular canal into the middle cranial fossa is a newly described etiology of vertigo. Three case studies of patients with CT evidence and surgical confirmation of bony dehiscence of the superior semicircular canal with variable presentations are described. The history, symptoms, CT findings, vestibular studies, and method of surgical repair are presented. Two patients had disabling vertigo and one had no vestibular symptoms. All underwent exploration via a middle cranial fossa approach with repair of the dehiscence. The bony dehiscence of the superior semicircular canal of the asymptomatic patient was identified and closed at the time of an encephalocele repair procedure. All patients did well postoperatively and both patients with vertigo improved. Bony dehiscence of the superior semicircular canal may cause vertigo or be asymptomatic and should be added to the differential diagnosis of vertigo.

**B**ony dehiscence of the superior semicircular canal (SSCD) is the absence of the bony covering over the membranous canal in the middle cranial fossa (Figure 1). Recently this dehiscence<sup>1</sup> has been associated with sound-induced vertigo (Tullio phenomenon<sup>2</sup>) and pressure-induced vertigo (Hennebert sign<sup>3</sup>). In addition, positional vertigo can be seen with bony dehiscence of the superior semicircular canal (SSCD).

A proposed mechanism of the induced vertigo is that the dehiscence acts as a third mobile

window into the labyrinth thus allowing sound or pressure waves to initiate perilymph flow in the superior semicircular canal (Figure 2). The perilymph flow induces ampulofugal deflection of the cupula and excitatory stimulation which results in nystagmus and the sensation of vertigo by the vestibuloocular reflex.

High-resolution computed tomographic images of the temporal bone in the coronal plane can be used to identify SSCD. In early reports, surgical confirmation of the dehiscence with repair of

the bony defect shows promising results<sup>1</sup> in the relief of vertigo.

We have identified three patients with CT evidence of SSCD who were subsequently explored surgically and the SSCDs closed.

### Case Report 1

Two years before presentation, Patient 1, a 50-year-old man began experiencing fluctuating hearing loss, vertigo, and aural fullness in his left ear. After unsuccessful endolymphatic sac decompression, he underwent a left vestibular nerve section which resulted in resolution of his left-sided vertigo. Shortly thereafter, he developed right-sided vertigo, hearing loss, aural fullness, and tinnitus. He presented to us with a diagnosis of bilateral Meniere's disease. His past medical history is significant for well-controlled type I diabetes mellitus, hypertension, and hypothyroidism.

On initial presentation, he had a symmetrical mixed hearing loss, bilateral aural fullness, tinnitus, and right-sided vertigo which was exacerbated by straining or bending. These weekly vertiginous episodes were associated with a room-spinning sensation and nausea which lasted from minutes to 1 hour. Dix-Hallpike examination with Frenzel lenses in the dark was positive. Electronystagmography (ENG) showed the expected left-sided absence of response and normal calorics on the right side. All laboratory tests including VDRL, ANA, ESR, and electrolytes were within normal limits. The patient was started on hydrochlorothiazide/triamterene.

A high resolution 1 mm axial and coronal CT scan of the temporal bone revealed a bony dehiscence of the superior semicircular canals bilaterally. After failure to respond to medical management, the patient underwent a right middle cranial fossa exploration and repair of the bony dehiscence over the right superior semicircular canal with calvarial bone and hydroxyapatite bone cement. The patient is currently 6 weeks post-operative and without vertiginous symptoms although the hearing loss and aural fullness have persisted.

### Case Report 2

Patient 2, a 48-year-old man with a 7-year history of intractable benign paroxysmal positional vertigo, despite multiple canalith repositioning

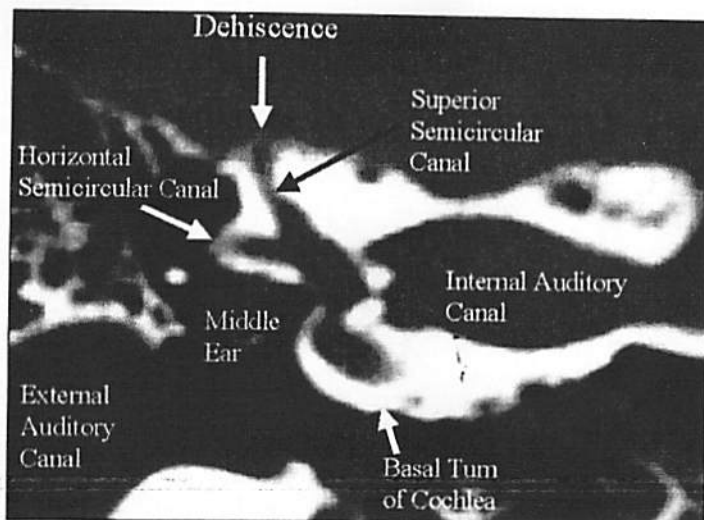


Figure 1. Superior semicircular canal dehiscence.

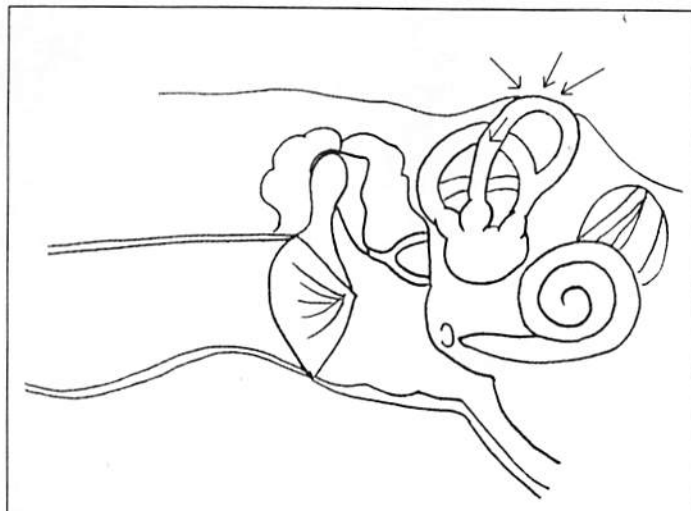


Figure 2. Changes in intracranial pressure induce perilymph flow.

maneuvers, presented to us for further treatment. His past medical history is significant only for type II diabetes mellitus. His vertigo lasted for seconds and was exacerbated by straining. There was no associated hearing loss, aural fullness, or tinnitus. On Dix-Hallpike examination, there was a positive response in the left ear down position. He had positional nystagmus by ENG in the head-back and head-right positions. Audiometry, otoacoustic emissions, ENG fistula test, calorics, vestibular autorotational test, and autorotational chair were all normal.

A previously obtained magnetic resonance image of the brain was reviewed and found to be normal. A high resolution 1 mm axial and coronal

CT scan of the temporal bones revealed a bony dehiscence over the right superior semicircular canal bilaterally. Since these symptoms severely interfered with the patient's occupation, he elected to undergo a right middle cranial fossa exploration with repair of the right SSCD with calvarial bone graft and hydroxyapatite bone cement. The right side was selected for repair since the symptoms seemed more severe as compared to the left. Postoperatively, he has done well with resolution of his vertigo and now experiences only occasional lightheadedness which does not interfere with his work. We elected not to perform a repair of the left SSCD because of the patient's symptomatic improvement.

### Case Report 3

Patient 3, a 51-year-old woman, presented with right chronic otorrhea and an ear canal mass. Two years previously, she had undergone a right tympanoplasty and mastoidectomy for a cholesteatoma. She also had had a revision right tympanoplasty and mastoidectomy with an ossicular chain reconstruction 2 months prior to presentation. A high resolution 1 mm axial and coronal CT scan of the temporal bone at that time revealed a right encephalocele and a bony dehiscence over the right superior semicircular canal. She was then referred to us for repair of her encephalocele.

She denied having any vertigo symptoms and had a normal Dix-Hallpike examination. No further vestibular workup was pursued. Her past medical history was significant only for hypertension. At the time of the encephalocele repair by a middle cranial fossa approach, multiple small tegmen dehiscences were identified. The encephalocele tegmen defect and the SSCD were repaired. Carved calvarial bone and hydroxyapatite bone cement were used to close the SSCD. Postoperatively, she has done well and has remained asymptomatic from a vestibular standpoint.

### DISCUSSION

Vertigo is a symptom with many etiologies<sup>4</sup> (Table). Recently, Minor described a new syndrome of sound and pressure induced vertigo associated with the absence of a bony covering over the right superior semicircular canal in the middle cranial fossa. Further work seems to confirm that

**TABLE**  
**Differential Diagnosis of Vertigo**

- |  |                                 |
|--|---------------------------------|
| • Acoustic neuroma                     |                                 |
| • Benign paroxysmal positional vertigo |                                 |
| • Central nervous system infection     |                                 |
| • Central nervous system tumor         |                                 |
| • Hyperthyroidism                      | • Ototoxic medications          |
| • Labyrinthitis                        | • Perilymph fistula             |
| • Meniere's disease                    | • Seizure disorder              |
| • Metabolic disorders                  | • Syphilis                      |
| • Migraine                             | • Vestibular neuronitis         |
| • Multiple sclerosis                   | • Vertebrobasilar insufficiency |
| • Oscillopsia                          |                                 |
| • Otosclerosis                         |                                 |

SSCD can cause vertigo and has even been associated with positional vertigo.

Patient 1 was unsuccessfully treated for Meniere's disease with medication and endolymphatic sac decompression and finally underwent vestibular nerve section. Repair of the SSCD resulted in resolution of the vertigo. Perhaps other patients who are diagnosed with vestibular disorders but do not respond to conventional treatment may have SSCD. The timely diagnosis and treatment of SSCD may result in better success in treating vertigo.

Patient 2 also had a previous diagnosis at presentation. Treatment of his benign paroxysmal positional vertigo with canalith repositioning maneuvers did not result in the expected improvement. After SSCD was diagnosed by high resolution CT scan and repaired, his vertigo resolved.

Patient 3 had no vestibular symptoms including vertigo despite the SSCD seen on CT scan and confirmed at the time of surgery. Clearly not every patient with SSCD has vertigo.

Although much work remains to be done, it seems that SSCD is a cause of vertigo in some patients while others are asymptomatic. At times these patients have been previously diagnosed and treated for other vestibular disorders and may represent treatment failures. High resolution CT scanning can be used to evaluate the temporal bone for SSCD in those patients who have vertigo and fail to respond to appropriate therapy. The incidence of SSCD in vertiginous patients and in the general population is not yet known. In unpublished data,

CT evidence of SSCD was found in 12 of 60 patients who had a temporal bone CT performed at our institution for the standard indications.

### CONCLUSIONS

The syndrome of bony dehiscence over the right superior semicircular canal is a newly identified cause of vertigo. We have described two patients with resolution of vertigo following repair of bony dehiscence over the right superior semicircular canal. The clinical findings associated with SSCD are varied and may include Tullio phenomenon, Hennebert sign, positional vertigo, or no symptoms at all. One patient with SSCD had no vestibular disturbances and two had disabling vertigo. Although the incidence of SSCD as a cause of vertigo is unknown at this time, it should be considered in the differential diagnosis particularly

in those patients who fail to improve with traditional therapies. Surgical intervention with repair of the SSCD has been demonstrated to relieve vertigo in selected patients.

### REFERENCES

1. Minor LB, Soloman D, Zinreich JS, et al. Sound- and/or pressure-induced vertigo due to bone dehiscence of the superior semicircular canal. *Arch Otolaryngol Head Neck Surg* 1998;124:249-258.
2. Tullio P. *Das Ohr und die entstehung der Sprache und Schrift*. Berlin: Urban Schwarzenberg; 1929.
3. Hennebert C. A new syndrome in hereditary syphilis of the labyrinth. *Presse Med Belg Brux* 1911;63:467.
4. Lee KJ. *Essential Otolaryngology*. Stamford, Conn: Appleton Lange; 1995:106-116.

*Dr Smullen is a resident and Dr Gianoli is Associate Professor with the Department of Otolaryngology-Head and Neck Surgery at Tulane University School of Medicine in New Orleans, La.*

*Mr Andrist is a medical student at Tulane University School of Medicine in New Orleans, La.*

# ONE SIZE DOES NOT FIT ALL

You wouldn't expect a size 40 suit to fit a 5-year-old, or an adult-sized life jacket to be safe for a toddler. So why should parents expect a hospital primarily for adults to care for children as well as one that treats children exclusively?

At Children's Hospital, we recognize that children aren't just small adults. Several different blood pressure cuffs are used by our staff to get the most accurate reading possible, whether it's for a premature, infant or a teenager. Our lab uses many different needles so even the tiniest patient will get only the smallest stick necessary. Even our physical therapists and psychologists tailor their care to the child's age.



CHILDREN'S  
HOSPITAL

So when your child needs emergency treatment, visit our Emergency Care Center. And talk to your pediatrician about Children's Hospital if your child needs to be hospitalized or needs an appointment with a pediatric specialist — because one size does not fit all.



200 HENRY CLAY AVENUE • NEW ORLEANS, LA 70118 • (504) 899-9511