6

Dizziness

Andrew J. Miller, MD
Gerard J. Gianoli, MD

Dizziness is a word patients use to describe unsteadiness, lightheadedness, whirling and floating sensations, headache, and imbalance. The three primary systems that control balance are the vestibular, visual, and proprioceptive systems–all of which are components of the central nervous system (CNS). Dysfunction of the vestibular system usually causes "true" vertigo, a sensation of spinning or an illusion of spinning motion, which must be distinguished from unsteadiness, lightheadedness, or a change in the awareness of the environment.

Anatomy

The vestibular labyrinth–the end organ of the peripheral vestibular system–and the cochlea comprise the inner ear, which is found in the petrous portion of the temporal bone. Each labyrinth is composed of a superior, posterior, and horizontal semicircular canal (SCC), a utricle, and a saccule (Fig. 6.1). The SCCs are orthogonal to each other and respond to angular acceleration. Each canal is composed of a dense bony capsule containing a membranous structure supported by a fluid that is high in sodium and low in potassium (perilymph). Inside the membranous labyrinth, the fluid is high in potassium and low in sodium (endolymph). Near the entrance of each canal into the vestibule, there is a dilation called the ampulla. An elevation inside each ampulla (the crista) contains hair cells that project into a

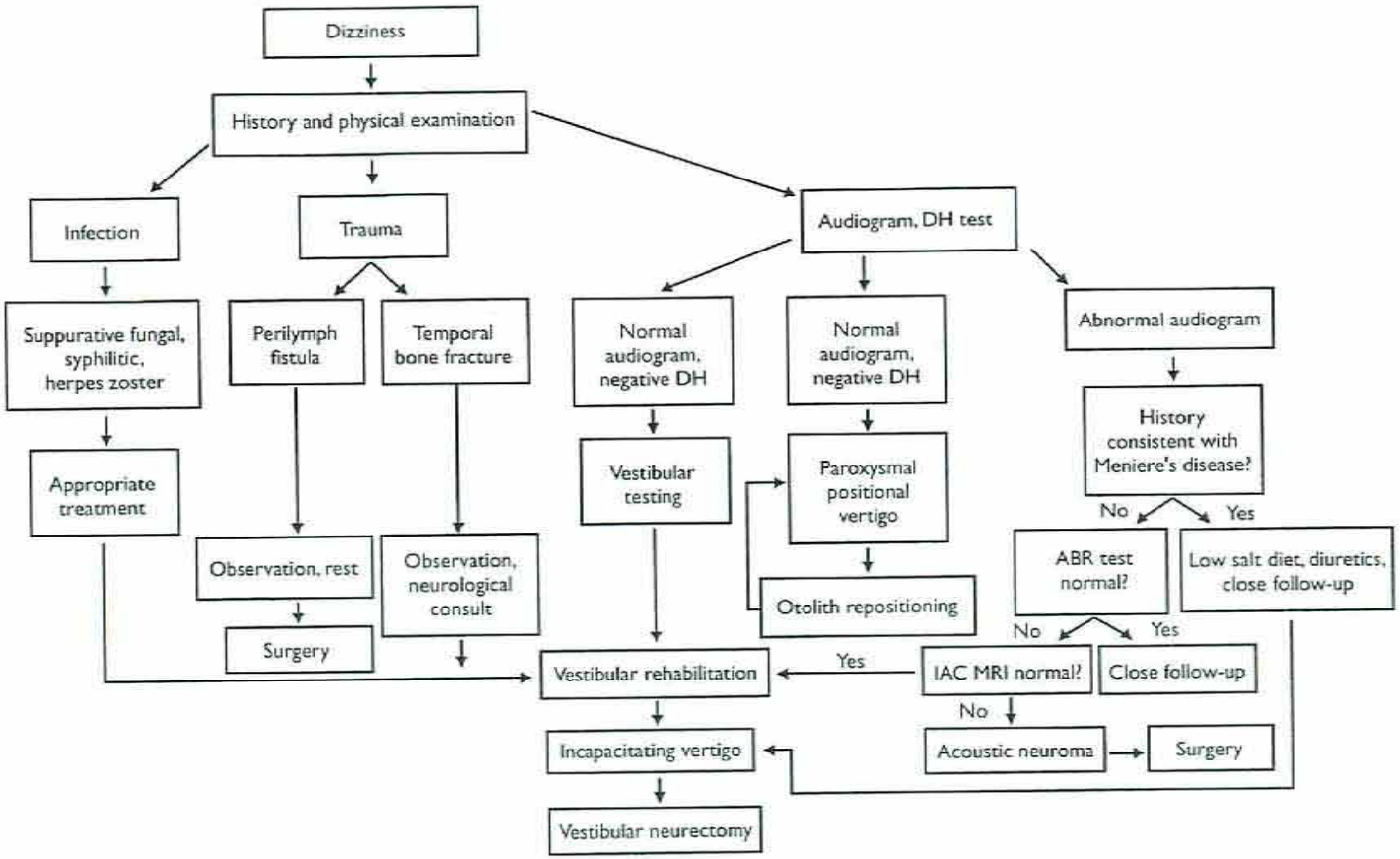

Algorithm Management of dizziness. ABR test = auditory brainstem response test; DH test = Dix–Hallpike test; IAC = image-analysis cytometry; MRI = magnetic-resonance imaging.

gelatinous material (the cupula) (*see* Fig. 6.1). The cupula responds to fluid motion in the canal, stimulating the hair cells. The utricle and saccule both contain an area of sensory epithelium (macula) that also have projecting hair cells; however, these hair cells project into a membrane (otoconia) upon which are many granules of calcium carbonate (1). These granules move in response to linear and gravitational acceleration, activating the hair cells. The utricle is excited by horizontal acceleration, whereas the saccule is sensitive to vertical acceleration.

Physiology

The right and left vestibular systems each emit baseline signals that the brain interprets as equal. When the activity on one side changes with respect to ac-

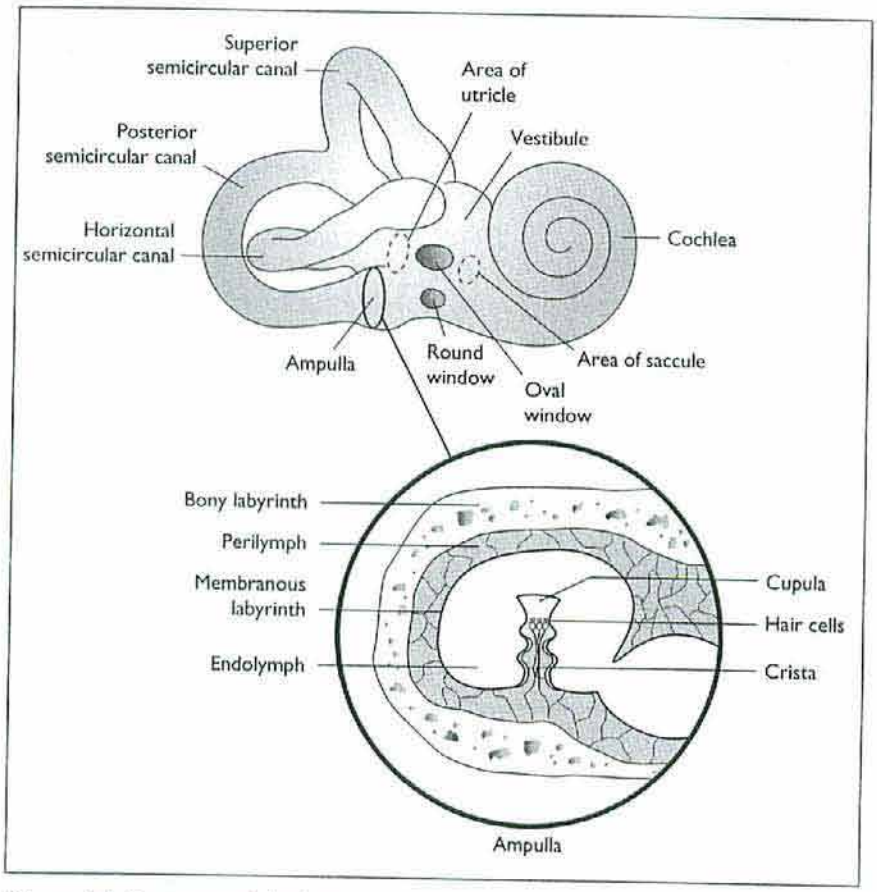

Figure 6.1 Structures of the bony labyrinth, with expanded view of the internal structures of an ampulla.

tivity on the other, complex responses are evoked (Fig. 6.2). One of these, the vestibulo-ocular reflex, keeps the eyes focused on an object while the head is in motion. Rotating the head activates the hair cells and sends a signal to the vestibular nucleus. The impulse travels to the contralateral sixth cranial nucleus, ascends the medial longitudinal fasciculus, and crosses to the third and fourth ipsilateral cranial nerve nuclei (*see* Fig. 6.2), resulting in the slow phase of eye movement in the opposite direction of the head turn. When one vestibular labyrinth is hypofunctional, the brain perceives the constant unequal signals between the two sides as persistent stimulation. Because the eyes cannot move indefinitely in one direction, the slow phase of eye movement is followed by a cortically generated, rapid, compensatory movement in the opposite direction (2). This rhythmic alternation between slow and fast eye motions is called nystagmus. By convention, the direction of the nystagmus is named for the direction of the fast component (i.e., "left-beating nystagmus" indicates fast movement in the left direction).

The vestibulospinal reflex results from activation of the vestibular system. The signal causes muscle contraction on the ipsilateral side and relaxation on the opposite side, resulting in a falling toward the side of hypoactivity.

The flocculonodular lobe of the cerebellum receives input from both the labyrinth and the vestibular nucleus, and its output possibly helps suppress vestibular hyperactivity (*see* Fig. 6.2). The vermis of the cerebellum receives input from the dorsal spinal cerebellar tract, which provides information on muscle position and tension. Multiple connections through the reticular system provide pathways to the phrenic nucleus, salivatory nuclei, and nucleus ambiguous and account for the vomiting, salivation, and regurgitation seen with some disorders. Connections between the reticular and sympathetic systems mediate pallor and sweating. Discrete tracts between the vestibular nucleus and the dorsal efferent nucleus of the vagus nerve contribute to nausea and vomiting during labyrinthine disturbance.

Over time, the CNS can become accustomed to prolonged vestibular inequalities. The visual and proprioceptive systems also assist in compensating for vestibular disorder (3).

History

One begins the history interview by attempting to understand the patient's use of the word *dizziness*, distinguishing between true vertigo (a sense of motion) and disequilibrium, lightheadedness, or imbalance. Note frequency, duration, time of onset, and cessation. Record the existence of the following symptoms:

- Hearing loss
- Tinnitus

- Nausea and vomiting
- Fever and chills
- Upper respiratory infection
- Headache
- Visual changes
- Otalgia
- Aural fullness
- Motion sickness
- Weakness
- Ataxia or falling to one side
- Facial numbness
- Chest pain
- Palpitations
- Sweating

Look for precipitating events such as a recent upper respiratory infection, head turning, change in position (e.g., going from sitting to standing), straining, history of head trauma, loud noises, chemical exposure, and menstruation. A positive history of any of the following conditions can influence symptoms and treatment:

- Birth defects
- Diabetes mellitus
- Thyroid disease
- Coronary artery disease
- Peripheral vascular disease
- Collagen vascular disease
- Autoimmunity
- Hypertension
- Allergic rhinitis
- Ear infections
- Endocrinologic, CNS, or ocular disorders
- Current medications
- Caffeine, alcohol, and salt consumption

A history of previous ear surgery is vital to diagnosis. Family and occupational histories may have implications for diagnosis and treatment.

Physical Examination

Vital signs may reveal **tachycardia**, **irregular pulse**, or hyper- or hypotension. Check **orthostatic hypotension** by recording the blood pressure with the patient in the supine position, and then again immediately on standing up. A difference of 20 mm Hg in these two systolic blood-pressure measurements

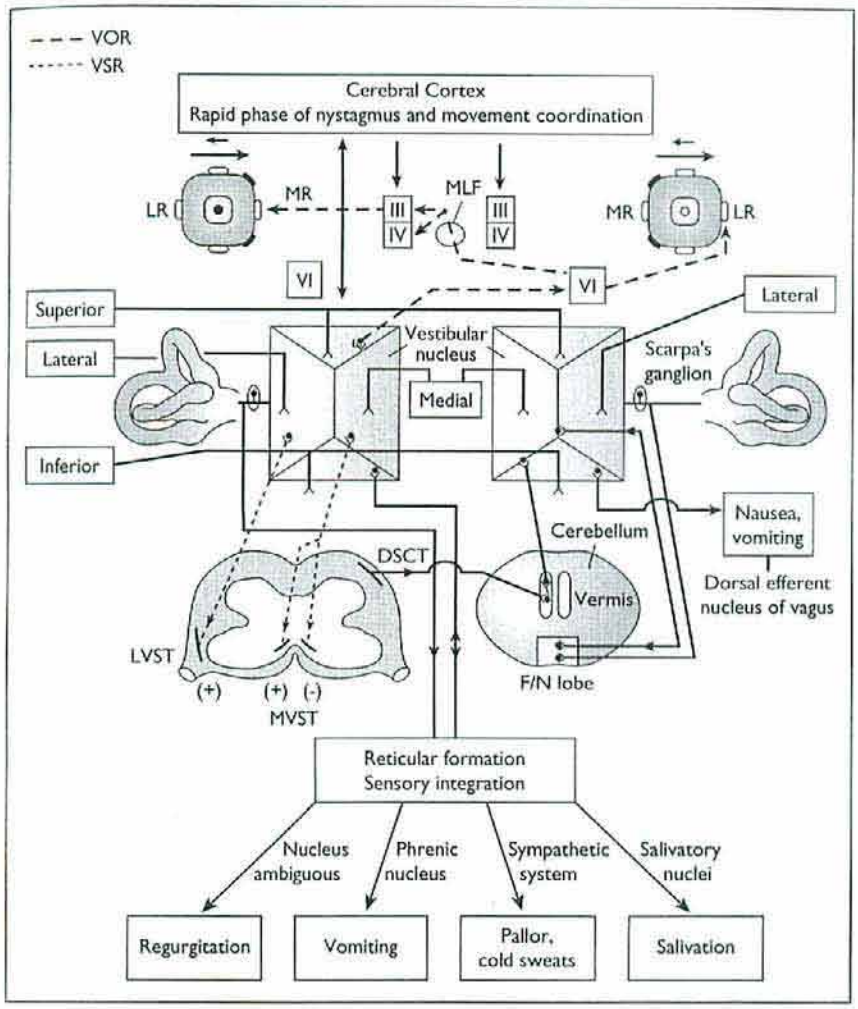

Figure 6.2 Pathways of the vestibular system. DSCT = dorsal spinal cerebellar tract; F/N lobe = flocculonodular lobe; LR = lateral rectus; LVST = lateral vestibular spinal tract; MLF = medial longitudinal fasciculus; MR = medial rectus; MVST = medial vestibular spinal tract; VOR = vestibulo-ocular reflex; VSR = vestibulospinal reflex.

(in a patient with a blood pressure in the normal range) is generally significant. The quality of the sensation felt by the patient usually is clearly lightheadedness or presyncope, not true vertigo.

Check the ears for **otorrhea**, perforated eardrum, and diminished hearing. Examine the eyes for **pupillary reaction**, nystagmus, retinal disease, and papilledema. Auscultate the neck for **carotid bruits**, then palpate for lymphadenopathy or thyromegaly. Follow this with testing of the cranial nerves.

Check **cerebellar function** with rapid, alternating hand motions. **Gait** is evaluated; a broad-based unsteady gait suggests cerebellar dysfunction. Perform the **sharpened Romberg test** by having the patient stand with his or her feet close together, arms folded, and eyes closed; watch for any swaying or unsteadiness. The **tandem walk** involves the patient standing with his or her arms folded, then walking a straight line, positioning his or her feet heel to toe; record estimates of proprioception, peripheral sensation, and strength. The Fukuda test, in which the patient marches in place with his or her eyes closed for 45 seconds, is useful because turning the body while marching in this manner indicates hypofunction of the vestibular system on the same side.

Nystagmus, if present, is an important indicator of vestibular dysfunction but difficult to detect during the usual physical examination. If the patient fixes his or her vision on any object, nystagmus will be suppressed. Furthermore, if the patient closes his or her eyes to avoid any visual fixation, nystagmus cannot be assessed. This dilemma is solved by using **Frenzel (+20 diopter) lenses**, which are so strong that looking through them makes everything blurry; hence, no visual fixation is possible. A tiny light in the Frenzel frame permits the examiner to see a patient's nystagmus in any gaze field (Fig. 6.3). The patient is asked to report the quality and time course of any dizziness experienced. Some vestibular testing laboratories have video-Frenzel equipment that projects the patient's eye movements onto a video screen and records them (Fig. 6.4).



Figure 6.3 These reasonably priced Frenzel lenses are battery powered and contain a small light within the frame to allow the physician to observe the patient's eye movements.

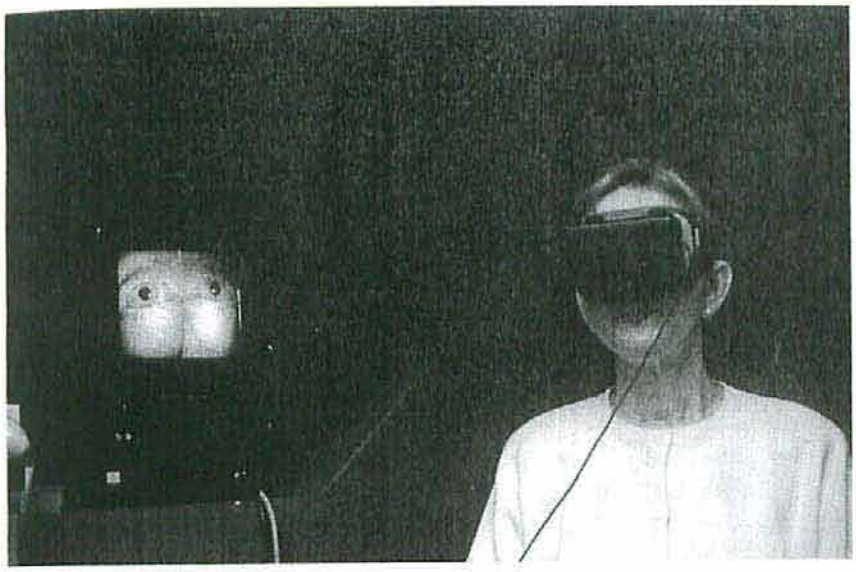

Figure 6.4 These video-Frenzel lenses have a small camera within the frame, allowing projection of the eye movement onto a video screen and recording it for later serial comparisons.

In the positioning test (**Dix–Hallpike maneuver**) (Fig. 6.5), the patient (in whom there has been no cervical movement restrictions or previous cervical spine surgery) sits up and, with his or her head turned to one side, quickly reclines (with help from the physician) until supine, with the head hanging over the edge of the table at 30° below the horizontal and still turned to the side. Watch the eyes for at least 20 seconds with Frenzel lenses in place and look for nystagmus; question the patient about any symptoms. Note the latency, duration, direction, and fatigability of any nystagmus. Then raise the patient back to a sitting position and again watch the eyes, noting any change in nystagmus or symptoms. The same maneuver is then repeated with the head turned in the opposite direction.

Caloric testing of the labyrinth can be done in the office. When the patient reclines 60° from the sitting position, the horizontal SCC is positioned vertically. With Frenzel lenses in place, the physician irrigates one ear with cool (30°C) water for 30 seconds. This causes the endolymph to move by convection in a direction that causes the vestibular output to be hypoactive with respect to the opposite side. Normally this is followed by nystagmus, with the slow phase toward the irrigated ear and the rapid phase toward the opposite direction (Table 6.1). After noting the nystagmus, the lenses are removed, and the patient fixates on a point to determine if the nystagmus is suppressed with fixation, as is normal. The opposite ear is then irrigated with cool water, and

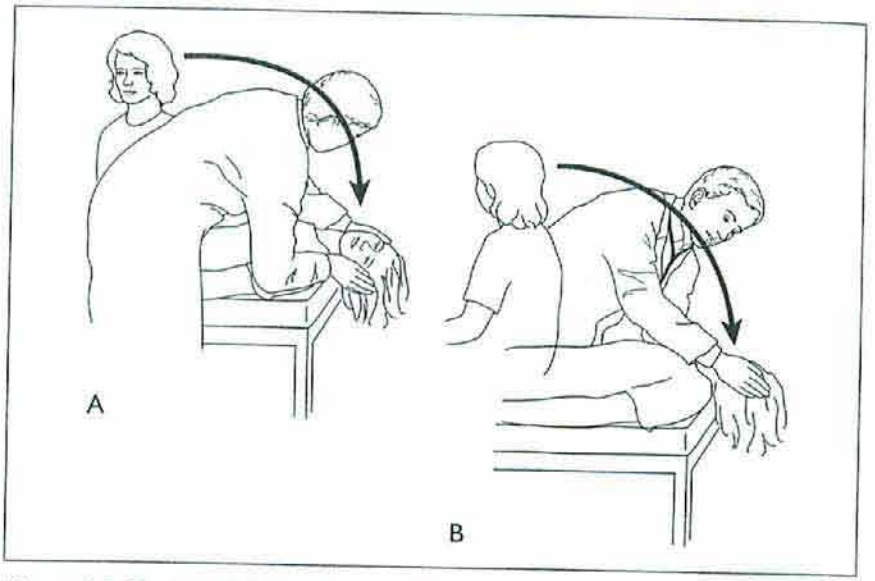

Figure 6.5 The Dix–Hallpike maneuver. **A,** The patient starts with the head turned to the left. The physician reclines the patient to the supine position, with the head hanging 30° off the edge of the table. After viewing any nystagmus, the patient is brought back to the sitting position, and the physician observes the eyes again. **B,** The maneuver is repeated, with the patient's head turned the other way.

Table 6.1 Results of Caloric Testing

Water Temperature	Ear	Eye (Slow Phase)	Eye (Fast Phase)
Cold	Right	Right	Left
Cold	Left	Left	Right
Warm	Right	Left	Right
Warm	Left	Right	Left

the physician observes the nystagmus, comparing the result to the first side. Next, the entire sequence is repeated with warm (44°C) water. This time, the nystagmus occurs in the opposite direction to that produced by the cool-water irrigation. Furthermore, the slow phase now is directed away from the irrigated ear, and the rapid phase is toward the irrigated side. If an irrigation system is not available, water may be injected into the external auditory canal using a 60-cm^3 syringe with an intravenous catheter tip.

Additional Diagnostic Evaluation

Because an underlying disorder can affect both hearing and balance systems, **audiometric testing** is routine. Testing for air- and bone-conduction thresh-

olds, speech discrimination, acoustic reflexes, and tympanometry is standard. The **auditory brainstem response test** can be useful when patient compliance is inadequate, and it can help locate the responsible lesion.

Many aspects of the specific vestibular testing performed during the physical examination may be evaluated with **electronystagmography (ENG)** (4), a quantitative examination of vestibular function that can enhance or even replace office caloric testing. ENG measures eye movement and is based on the difference in voltage between the cornea (positive) and the retina (negative). The patient must abstain from drinking alcohol and taking anticholinergics, antihistamines, barbiturates, and other CNS depressants for 1 week before testing. Electrodes are applied to the patient's face above, below, and lateral to the eyes to record the corneoretinal potential (Fig. 6.6). Next, a series of evaluations amounting to an extension of the caloric examination (described earlier in this chapter) is performed in a dark room, and the results are recorded automatically on chart paper. The details of the ENG examination are beyond the scope of this chapter, but interested readers can consult the references provided (5).

Advanced tests of vestibular function are available in specialized centers (6). **Sinusoidal harmonic acceleration** uses a spinning chair to increase diagnostic sensitivity (Fig. 6.7). Some practitioners obtain useful information from **vestibular autorotation testing**, during which the patient moves his or her own head in both the horizontal and vertical planes. These tests may be

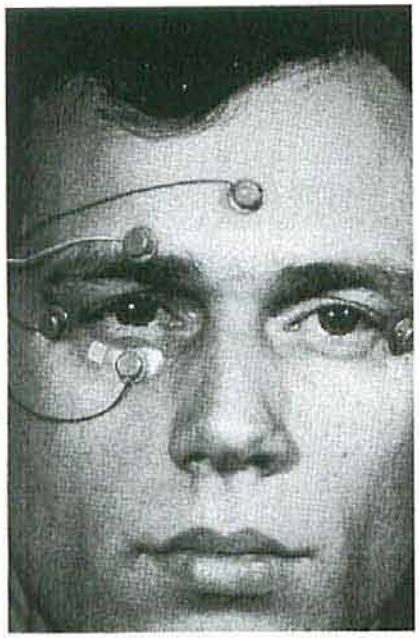

Figure 6.6 The placement of the electrodes around the patient's eyes during ENG testing.

Figure 6.7 Rotation chair testing, used with the video-Frenzel lenses.

able to identify early vestibular dysfunction and can assist in vestibular rehabilitation. **Dynamic posturography** helps localize the disorder to the vestibular, visual, or proprioceptive systems by using the various combinations of open or covered eyes, a stable or moving horizon, and a stable or moving platform (Fig. 6.8).

Laboratory testing can be used when the history suggests a systemic cause of the dizziness, such as coronary artery disease, cardiac arrhythmias, peripheral vascular disease, diabetes mellitus, hypertension, hypothyroidism, and collagen vascular disease. Tests that may prove helpful include antinuclear antibody level, erythrocyte sedimentation rate, rheumatoid factor, fluorescent treponemal antibody absorbance (FTA-Abs), complete blood count, and PT/PTT (looking for hypercoagulable states). Cervical spine radiography can confirm cervical arthritis or calcified vessels.

High-resolution axial and coronal temporal bone CT (computed tomography) scans show bony structures, congenital malformations, temporal bone fractures, or infectious processes in the ear. A magnetic resonance imaging (MRI) scan, including T_1- and T_2-weighted images and T_1 with gadolinium, is useful for evaluating possible cerebellopontile-angle masses.

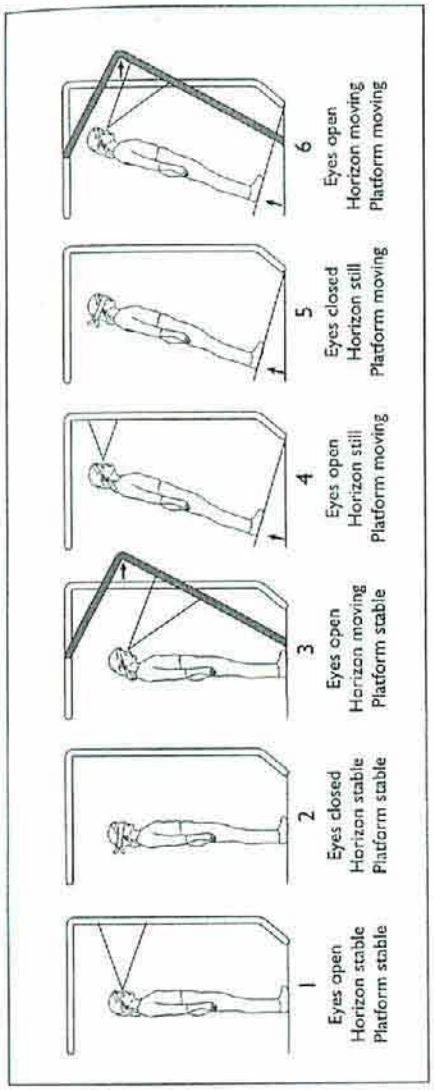

Figure 6.8 The six positions used in posturography.

Differential Diagnosis

Although the differential diagnoses for dizziness are numerous (Table 6.2), a comprehensive history (Table 6.3) and physical examination with directed evaluation can limit the options considerably. Some causes affect only the peripheral vestibular system (including the labyrinth, vestibular nerve, and vestibular nucleus), whereas other types of pathology affect the CNS; some

Table 6.2 Differential Diagnosis of Dizzines

Idiopathic Disorders

Meniere's disease

Infection

Vestibular neuronitis
Herpes zoster oticus
Suppurative labyrinthitis
Serous labyrinthitis
Otitis media/externa
Syphilis
Fungal infection
CNS infection

Trauma

Benign paroxysmal positional vertigo
Temporal bone fracture
Perilymph fistula
Labyrinthine concussion
CNS trauma (subdural hematoma)
Cerebellopontine-angle masses
Neoplasm (acoustic neuroma, meningioma)
Cholesteatoma
Cholesterol granuloma
Aneurysm

Allergic and Immunologic Disorders

Autoimmune inner ear disease
Allergic reaction
Cogan's syndrome
Relapsing perichondritis

Endocrine/Metabolic Disorders

Diabetes mellitus
Hypothyroidism
Addison's disease

Central Nervous System Disorders

Epilepsy
Multiple sclerosis
Cerebellar disorders

Cardiovascular Disorders

Vascular Disorders

Hypertension
Vertebrobasilar insufficiency
Transient ischemic attack
Stroke
Wallenberg's syndrome
Subclavian steal
Vascular-loop compression syndrome
Carotid sinus syndrome
Postural hypotension
Migraine headache or equivalent
Blood components
Hyperviscosity
Anemia
Decreased oxygen capacity

Cardiac Disorders

Arrhythmia
Cardiac failure
Hypoxia

Pediatric Disorders

Congenital anomalies
Hereditary syndromes
Arnold–Chiari syndrome
Large vestibular aqueducts
Perilymph fistula
Benign paroxysmal vertigo (in children)

Other Disorders

Toxic agents
Ocular disorders
Proprioceptive disorders
External and middle ear disorders
Motion sickness
Aging
Psychogenic disorders

CNS = central nervous system.

processes affect both systems. The general diagnosis and management Algorithm may assist in arriving at the correct diagnosis and starting treatment. However, it is important to remember that symptom complexes of many processes can overlap, so a complete understanding of the specific causes of dizziness is desirable.

Table 6.3 Key Points of History

Patient's definition of dizziness (vertigo vs. unsteadiness or lightheadedness)	Past medical history
Time course and pattern	Past surgical history
Presence of hearing loss, tinnitus, or aural fullness	Factors that improve or worsen dizziness
Associated symptoms	Drug, cigarette, caffeine, or alcohol use
Precipitating factors	Family history
	Occupational history

Diagnosis and Management of Specific Disorders

The Algorithm outlines the decision-making steps in the management of dizziness.

Meniere's Disease

Meniere's disease is a vestibular disorder usually presenting in adults 30 to 50 years of age. The classic symptoms are episodic vertigo; low-pitched tinnitus; fluctuating, low-frequency sensorineural hearing loss (SNHL); and a feeling of fullness in the affected ear. The vertigo is intense for 1 to 2 hours, followed by unsteadiness for a few days. The hearing loss and tinnitus usually resolve after an attack but may increase with each episode, and the vertigo may persist. Drop attacks (**"crisis of Tumarkin"**), during which the patient loses extensor tension and falls to the ground fully conscious, may occur late in the disease. The cause of Meniere's disease is unknown, but autoimmunity, endocrine disorder, and disturbed labyrinthine electrolyte balance are suspected. The diagnosis is made by the history because the physical examination is normal except during an attack. Audiometry shows low-frequency SNHL, and ENG shows hypoactivity on the affected side (7).

The treatment begins with eating a low-salt diet, avoiding tobacco and caffeine, and taking a diuretic (hydrochlorothiazide). **Vestibular suppressants** are needed only during an acute attack. If medical treatment fails, surgery (e.g., endolymphatic shunt, vestibular nerve section, labyrinthectomy) may help. Chemical destruction of the vestibular system with transtympanic aminoglycosides has succeeded in controlling vertigo in some patients (8). Case 6.1 provides an example of a patient with Meniere's disease who initially did well with medical therapy but who eventually required surgical intervention.

Infections

Vestibular neuronitis typically follows a nonspecific viral illness. It begins with an episode of severe vertigo that lasts weeks to months and is accompanied by

Case 6.1 Man with Meniere's Disease

A man 47 years of age presented with a history of sudden-onset vertigo 3 days before his current visit. The vertigo began in the mid-morning while he was at work and increased in intensity over an hour to the point he was nauseated and vomiting. Unable to work, he took a meclizine tablet and was driven home by a coworker. Later that afternoon, he felt much improved but "drained." He had noted a sense of fullness and buzzing in his right ear on awakening that morning, and the sensation has persisted up to now.

His past medical history is pertinent because he had experienced a similar, less-severe episode 4 years ago that lasted only 3 hours. An audiogram done at that time demonstrated a right SNHL, and he was diagnosed with presumptive Meniere's disease. He had been symptom free between the attacks. He denies having any other neurological symptoms, headache, cardiac disease, and hypertension. He is taking no medication except for the meclizine he had begun at the time of his first vertigo event.

Physical examination is normal, with normal ears and no evidence of any cardiac or neurological abnormality. An audiogram is preformed and reveals a right-sided SNHL of 40 dB, a 15-db increase since his first audiogram. Speech discrimination scores were normal. An MRI scan is obtained and reveals no evidence of acoustic neuroma or other abnormality.

The patient is counseled about the natural history of Meniere's disease and is begun on a thiazide diuretic. He does well initially, but within 2 years is experiencing several attacks each month, many of which require that he leave work. He is asked whether further treatment might be possible, particularly due to the effect on his employment and his ability to safely operate an automobile. After consultation with a neurotologist, the decision to proceed with vestibular nerve section is made. Several other treatment options are discussed, including endolymphatic shunt and vestibular ablation with intratympanic gentamicin, but he and his surgeon decide on retromastoid craniotomy and nerve section. The procedure is performed uneventfully, and he is discharged on the second postoperative day with minimal residual vertigo. However, he experiences significant postoperative disequilibrium and begins outpatient vestibular adaptive exercises 1 week after surgery. He is able to return to work within 3 weeks and notes progressive improvement over the next 3 months. He has no further attacks of vertigo but has minimal residual disequilibrium with rapid head movement, to which he has accommodated easily.

Discussion

Meniere's disease is a life-long chronic disease that is managed by progressive levels of intervention. Some patients experience only minimal, infrequent symptoms and require no treatment. Others who are more symptomatic respond to diuretics, and a few may require surgical management. In older individuals for whom surgical management is not an option, vestibular ablation with intratympanic gentamicin is often effective. Treatment decisions are best made in consultation with a neurotologist—a subspecialist who treats diseases of the ear and cerebellopontile angle. Patients often request disability for Meniere's disease but should be advised that treatment is available for the symptoms of the disease and that the assumption of a sedentary lifestyle or disability is not the optimal strategy.

nausea and vomiting. Hearing usually is not affected (9). There is spontaneous nystagmus toward the unaffected ear and hypoactivity of the involved side on ENG. Treatment consists of rehydration, vestibular suppressants, and rehabilitative vestibular exercises. Case 6.2 illustrates a typical case of vestibular neuronitis.

Case 6.2 **Man with Vestibular Neuronitis**

A man 35 years of age awakens with profound vertigo, nystagmus, and nausea and is unable to walk without assistance. He is taken to the emergency department of the community hospital for evaluation. He has had no previous episodes and has no significant past medical history.

Review of symptoms is unremarkable, with the exception of an upper respiratory infection the previous week. His vital signs are normal, with the exception of mild tachycardia. He has a brisk left-beating nystagmus that did not alter with changes in position. He is profoundly nauseated and has vomited several times. Neurological examination fails to reveal any specific muscle weakness or sensory changes, and cranial nerve testing is normal. He states that his hearing seems to be normal and does not note any headache or nuchal rigidity.

An electrocardiogram and an urgent head CT scan with contrast are normal.

He is diagnosed with probable vestibular neuronitis and admitted for intravenous fluids and vestibular sedation with parenteral benzodiazepam. He improves significantly after therapy and was able to resume eating within 24 hours. An audiogram is normal, and the diagnosis of vestibular neuronitis is confirmed. After discharge, he continues to improve and, several weeks later, has only minimal disorientation with sudden head movement. These symptoms abate slowly, but he notes persistent minor disequilibrium for months.

Discussion

This case illustrates typical vestibular neuronitis, i.e., an isolated episode of severe vertigo with associated nausea but without hearing loss. The diagnosis is one of exclusion, because other injury to the vestibular portion of the eighth cranial nerve or vestibular nuclei (secondary to infarct or brainstem neoplasm) may mimic this diagnosis. The presentation at a young age and the history of a recent viral upper respiratory infection suggest the diagnosis. Imaging usually is not required, especially in the absence of focal neurological signs, unilateral hearing loss, or recurrent or persistent symptoms.

The persistent disequilibrium that often follows acute vestibular disorders is due to permanent residual dysfunction and can be troublesome for patients. If this patient had been employed as a roofer, steel erector, or other similar occupation, he would have to quit his job. Younger patients typically accommodate rapidly, but older patients can become essentially disabled. Accommodation can be enhanced by activity, avoidance of vestibular suppressants, and formal vestibular exercises taught by a physical therapist versed in vestibular rehabilitation. Classic BPPV may occur later in these patients and may respond to otolith repositioning.

Herpes zoster oticus (Ramsey–Hunt syndrome) presents with facial pain and vesicles on the skin of the external ear; it can be accompanied by hearing loss, tinnitus, vertigo, and facial paralysis. Treatment includes oral acyclovir 800 mg five times daily for 7 to 10 days, corticosteroids, rehydration, and evaluation by an otologist if facial palsy occurs.

Suppurative labyrinthitis, a bacterial infection of the inner ear, is a medical and surgical emergency that arises from a middle ear infection. It also can result from bacterial meningitis spreading to the inner ear through the internal auditory canal or cochlear aqueduct. Chronic otitis media may erode the horizontal SCC wall, allowing bacterial invasion of the inner ear. Symptoms include fever, chills, nausea, vomiting, severe vertigo, profound and permanent SNHL, and nystagmus. ENG shows hypoactivity of the affected ear. The patient requires immediate hospitalization, intravenous fluids, antiemetics, vestibular suppressants, and treatment of the initiating pathology. Steroids given concomitantly with the antibiotics may prevent hearing from deteriorating further. The severe vertigo peaks in 24 hours and resolves in a few days, but persistent disequilibrium may require rehabilitative vestibular exercises. Although most patients respond to medical therapy, there are those whose symptoms worsen or remain the same. Others may develop intracranial complications, requiring surgical intervention.

Syphilis must be considered in the diagnosis of vertigo and progressive or fluctuating SNHL. Congenital syphilis can occur as a severe early infection or as a more insidious latent form. Secondary syphilis may present with luetic labyrinthitis caused by meningoencephalitis. Tertiary syphilis causes inflammation and fibrosis in the inner ear. Hennebert's sign (vertigo and nystagmus on pneumatic otoscopy) and Tullio's phenomenon (vertigo and nystagmus in response to intense sound) may be seen. Laboratory tests (e.g., rapid plasma reagin test, Venereal Disease Research Laboratory test for syphilis) confirm active infection, whereas the FTA-Abs test establishes previous infection. Treatment is penicillin for 3 months. Corticosteroids may improve auditory function.

Fungal infection of the labyrinth is seen mainly in the immunocompromised patient. Common infections are candidiasis, aspergillosis, mucormycosis, cryptococcosis, and blastomycosis. Systemic antifungal agents with aggressive surgical debridement may avoid the usual poor outcome.

Serous Labyrinthitis

Serous labyrinthitis, a severe noninfectious inflammatory process of the inner ear, results from the introduction of toxic substances into the labyrinth (e.g., chemicals, products of otitis media, allergens), with no evidence of bacterial invasion. Vertigo is less severe, and hearing loss is usually minimal. As

with otitis media, aggressive antimicrobial treatment is warranted to prevent suppurative labyrinthitis. A pressure-equalizing tube inserted through the tympanic membrane also can help alleviate symptoms. Vertigo and hearing loss usually subside gradually.

Trauma

Head trauma can cause symptoms of vertigo (due to vestibular injury) and disequilibrium and lightheadedness (secondary to CNS injury [e.g., stroke]).

Benign paroxysmal positional vertigo (BPPV) can be caused by trauma, infection, surgery, or aging (10). In BPPV, a few otoconia are dislodged from the macula and find their way into the posterior or horizontal SCCs. These otoconia may roam free in the canal (**canalithiasis**) or adhere to the cupula (**cupulolithiasis**). With head motion (e.g., rolling over in bed), the resulting otoconia movement stimulates the hair cells, inducing vertigo. This can be reproduced by the Dix–Hallpike maneuver (*see* Fig. 6.5). Patients may complain of a constant vague dizziness secondary to cupulolithiasis, which is thought to transform the SCC from an angular-acceleration detector to a linear-acceleration or gravity detector. With posterior SCC BPPV, nystagmus appears after a short latency and is rotary in the direction of the ear that is turned down. In horizontal SCC BPPV, nystagmus is immediate and horizontal toward the turned-down ear. Vestibular exercises and canalith repositioning are the initial treatment (Case 6.3) (11,12).

Canalith repositioning is based on the theory that the otoconia can be rotated from the SCC into the vestibule (Fig. 6.9). For posterior SCC BPPV, the patient lies supine with the affected ear down. At 30-second intervals, the physician gradually turns the patient's head to the opposite side while turning his or her entire body to the opposite side as well, finally bringing the patient back to the sitting position. A mastoid vibrator helps facilitate otoconia movement.

For horizontal SCC BPPV, the patient begins in the supine position with the affected ear down. At 30-second intervals the patient's head and body are turned a complete 360° (*see* Fig. 6.9) (11). After the procedure, the patient keeps his or her head elevated and avoids rapid turning or bending for 3 days. If these measures fail, surgical interventions (e.g., **posterior SCC occlusion, singular neurectomy**) are available.

Most **temporal bone fractures** are a combination of the two types, transverse and longitudinal. A transverse temporal bone fracture results from a severe blow to the frontal or occipital areas and carries a high incidence of severe vertigo and SNHL secondary to disruption of the labyrinth. The tympanic membrane is intact, and nystagmus is seen to the side contralateral to the injury, with facial paralysis in 50% of the patients. Severe vertigo can be controlled with vestibular suppressants until it subsides in approximately 1

Case 6.3 **Woman with Benign Paroxysmal Positional Vertigo**

A woman 52 years of age presents with a complaint of awakening with the room spinning. After nearly a minute, the dizziness seems to clear. However, when she tries to get out of bed, the vertigo recurs, lasting 15 to 30 seconds. As the day goes on, she has gradual improvement, but many times during the day notes several seconds of vertigo. She does not experience nausea, denies tinnitus and hearing loss, and has no history of ear disease.

Physical examination reveals normal vital signs, no nystagmus, and normal neurological examination. Tympanic membranes and gait are normal. Tuning fork and cerebellar tests are all normal. A Dix–Hallpike test reveals brisk, downbeating, rotatory nystagmus with the right ear down. Vertigo appears 6 seconds after being placed in the precipitating position, increases for 15 seconds, then resolves by the end of 1 minute, duplicating her complaint. Repeating the test several minutes later demonstrates reduced nystagmus and symptoms of vertigo.

An audiogram is normal, and she is diagnosed with BPPV. An otolith-repositioning procedure was performed, and she was instructed to maintain her head in the upright position for 24 hours. When contacted by the office nurse 2 days later, the patient has no recurrence of her symptoms.

Nine months later, she represents with similar symptoms of a somewhat lesser degree. A second Dix–Hallpike test was positive, and an otolith repositioning maneuver was performed again with excellent response.

Discussion

This patient presented with the classic symptoms of BPPV. Her initial attack probably occurred when she rolled over in bed as she was awakening. The nystagmus began after a short latency and was fatigable, classic for BPPV. The clinical response to repositioning is often dramatic and can be repeated if the symptoms recur, which they typically do. This diagnosis is important to rule out, because it often is treated easily. Using meclizine is discouraged because vestibular suppressants are unlikely to improve the symptoms.

week; residual unsteadiness may last for 3 to 6 months. Prompt referral to the specialist is important if there is facial nerve paralysis; surgical decompression of the bony canal may be necessary.

Longitudinal temporal bone fractures are more common than transverse fractures and usually result from a blow to the side of the head. The external auditory canal and tympanic membrane may be lacerated and, with ossicular discontinuity, can cause conductive hearing loss. Facial nerve paralysis is observed in only 20% of patients, and SNHL is much less common. Vertigo is usually mild, presenting with changes in head po-

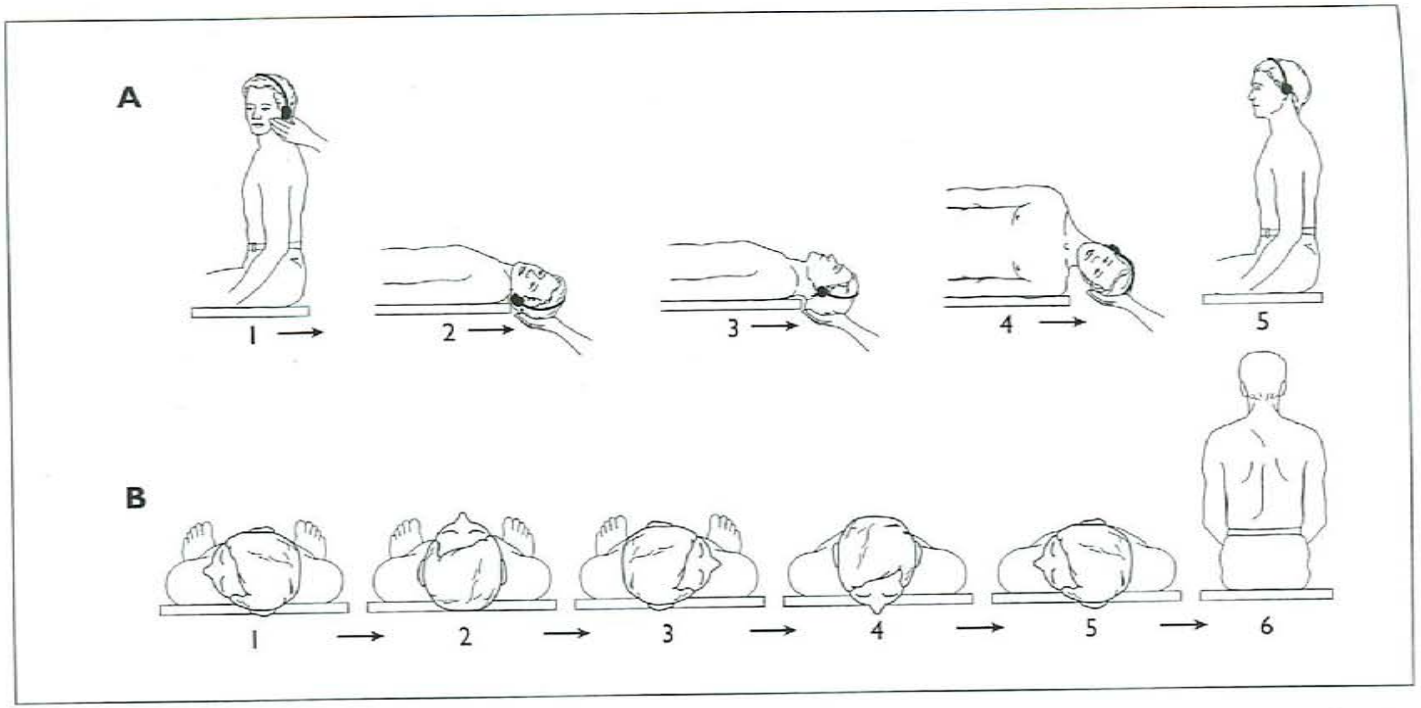

Figure 6.9 Canalith repositioning procedure (CRP). **A,** CRP for posterior semicircular canal (SCC) benign paroxysmal positional vertigo (BPPV) starts with the patient in a seated position and his or her head turned to the affected ear. With the mastoid vibrator in place, the patient then is moved through each position in 30-second intervals, arriving back in the sitting position. **B,** CRP for horizontal SCC BPPV starts with the patient in the supine position with his or her head turned to the affected ear. The patient then is moved through each position in 30-second intervals, with the mastoid vibrator in place, arriving back in the sitting position.

sition and often resolving after rehabilitative vestibular exercise (*see* section on Management below).

Controversy surrounds the cause of perilymph fistula (PLF), the leakage of perilymph from the oval or round windows. It may result from trauma, infection, strenuous physical activity, scuba diving, or airplane travel or may simply occur spontaneously (13). The patient presents with vertigo, fluctuating or sudden SNHL, tinnitus, and aural fullness much like Meniere's disease, and symptoms may be increased by straining. The physical examination is not much help, but some patients may have vertigo and nystagmus on pneumatic otoscopy (positive fistula test) (14). With a large PLF, cerebrospinal fluid otorrhea may be encountered, as shown by the presence of β_2-transferrin. High-resolution CT scan usually does not reveal the presumptive fistula except in children with a malformation of the temporal bone.

Treatment is bedrest, head elevation, antitussives, stool softeners, and reduced physical activity. If the symptoms appear after a head trauma, the fistula may be the result of a dislocated stapes, and surgical repair may be necessary. Some surgeons explore the middle ear in PLF patients who do not respond to medical treatment. In such cases, surgery involves patching the oval and round windows with soft tissue. This procedure often helps vertigo but rarely restores hearing. Vertigo in patients with a history of otologic surgery, especially stapedectomy, deserves prompt referral to an otologist with a presumptive diagnosis of PLF.

A **labyrinthine concussion** may cause vertigo and SNHL. Although SNHL may not improve, vertigo and disequilibrium usually respond to vestibular exercises. One must not confuse this with subdural hematoma, which also can cause unsteadiness after head injury.

Cerebellopontile-Angle Masses

Cerebellopontile-angle masses include neoplasms, cholesterol granuloma, cholesteatoma, and aneurysms (Case 6.4), but the most common mass by far is acoustic neuroma. (Meningiomas, glomus tumors, CNS tumors, and other neuromas make up a smaller percentage.) Acoustic neuromas are benign, grow slowly, and originate from Schwann's cells of the vestibular nerve. Patients with an acoustic neuroma are more likely to present with unsteadiness than with vertigo. The mass encroaches on the cochlear nerve, with progressive asymmetrical SNHL marked by loss of speech discrimination. ENG may be hypoactive. Cranial nerve V (and, later, cranial nerves VII, IX, X, and XI) may be affected. Approximately 15% of patients with an acoustic neuroma present with acute vertigo and a sudden, asymmetrical SNHL, suggesting cochleovestibular cerebrovascular accident. MRI with gadolinium of the internal auditory canals demonstrates

Case 6.4 **Man with Vertigo Caused by a Cholesteatoma**

A man 58 years of age presents to the emergency department with an acute attack of vertigo and associated nausea and vomiting. The patient is unemployed and uninsured and has not sought treatment for any aliment for many years. He has a long history of drainage from his left ear and has not been able to hear from that ear since childhood.

Physical examination reveals a thin, unkempt man with a strong odor of alcohol and a brisk right-beating nystagmus. He is unable to walk and cannot stand without assistance. The nystagmus does not change with positional changes, nor does it fatigue with time. Facial nerve function and the remainder of the neurological examination are normal. Otologic examination reveals foul drainage in the left ear canal. After suctioning the canal, microscopic examination reveals a large cholesteatoma with erosion of the ear canal and granulation tissue obscuring the margin of the erosion.

The patient is admitted and intravenous benzodiazepam is administered, markedly decreasing his symptoms. An urgent head CT scan with contrast and 1-mm cuts through the temporal bone reveal a large lucency in the left mastoid cavity, with erosion of the lateral semicircular canal. There is no evidence of intracranial fluid collection or enhancement of the dura to suggest intracranial extension. An audiogram demonstrates profound hearing loss in the affected ear; however, because of the normal hearing of the contralateral ear, adequate masking could not be performed to determine accurately the degree of conductive loss.

The patient is placed on intravenous antibiotics and local ear care. Several days later he undergoes modified radical mastoidectomy and removal of the cholesteatoma and fascial grafting over the fenestration in the horizontal semicircular canal. His vertigo gradually improves, although he is left with significant permanent disequilibrium for which he is prescribed vestibular rehabilitation as an outpatient. His hearing does not return, and he becomes lost to follow-up after his third postoperative visit.

Discussion

Vertigo can be the initial manifestation of inflammatory ear disease; however, other symptoms (e.g., pain, hearing loss) typically occur first. Most patients encountered in a physician's office have been evaluated previously; hence, large infected cholesteatomas are rare. However, in underserved areas where routine health care is not readily sought or available, cases such as this are still encountered.

the tumor. Treatment usually involves surgical excision, with stereotactic radiation reserved for patients unsuited for general anesthetic or unwilling to undergo operation. In reviewing reported results of treatment, one must differentiate between simply preserving a patient's hearing and preserving his or her *useful* hearing.

Allergic and Immunologic Diseases

Autoimmune inner ear disease may present with vertigo or disequilibrium and a rapidly progressive or fluctuating SNHL that may be asymmetric. Symptoms may be associated with rheumatoid arthritis, scleroderma, or systemic lupus erythematosis. Tests for antinuclear antibody, rheumatoid factor, erythrocyte sedimentation rate, and antibodies to inner ear antigens (with the lymphocyte transformation test or a Western blot assay looking for antibodies to the 68-kD inner ear protein) may assist in establishing a diagnosis (15). These tests have shown moderate sensitivity and high specificity to autoimmune diseases of the inner ear.

Treatment consists of high-dose steroids for 4 weeks, tapering off as symptoms allow. If no benefit is seen, a cytotoxic agent (e.g., cyclophosphamide) or plasmapheresis may be appropriate.

Cogan's syndrome (autoimmune interstitial keratitis, episodic severe vertigo, progressive SNHL, and tinnitus) can be seen with systemic disorders or vasculitides such as rheumatoid arthritis, polyarteritis nodosa, or inflammatory bowel disease (16). The interstitial keratitis of Cogan's syndrome produces rapid visual loss with inflammatory symptoms, whereas the interstitial keratitis of syphilis is insidious and without acute inflammation. Treatment is with steroids; if there is no response, cytotoxic agents are added.

Allergic reaction to various substances may cause symptoms of vertigo, hearing loss, and tinnitus usually through a non–IgE-mediated process that causes edema of the labyrinth. The symptoms usually resolve once the allergen is removed. Allergy testing and immunotherapy may prevent future episodes.

Endocrine and Metabolic Diseases

Diabetes mellitus may induce dizziness by a variety of mechanisms (17). Hypo- or hyperglycemia may evoke lightheadedness. Damage to small vessels due to diabetes mellitus may cause labyrinthine ischemia. Diabetes mellitus also can cause a primary neuropathy of the vestibular nerve. **Hypothyroidism** may present with dizziness, SNHL, tinnitus, aural fullness, and other symptoms of hypothyroidism, such as weight gain, dry skin, and constipation. The symptoms improve with thyroid replacement therapy. **Addison's disease** (adrenocortical insufficiency) may cause lightheadedness and postural hypotension.

Cardiovascular Diseases

Cardiovascular diseases can produce varying degrees of cerebral anoxia, resulting in complaints of imbalance, unsteadiness, or lightheadedness that are

often presyncope (Case 6.5). If the disorder affects the blood supply to the labyrinth or to the vestibular nucleus, the patient may present with true vertigo. The internal auditory artery supplies blood to the labyrinth and is a branch of the anterior inferior cerebellar artery, which derives from the vertebrobasilar artery system. Because the internal auditory artery is an end artery, any disease affecting it or its feeding vessels may result in ischemia to the labyrinth, causing vertigo and hearing loss (18).

Many patients believe that **hypertension** causes dizziness; however, more often dizziness is a side effect of the medications used to treat hypertension. **Atherosclerosis**, when present in the vertebrobasilar artery system, can result in vertebrobasilar insufficiency, causing dizziness, vertigo, syncope, ataxia,

Case 6.5 **Man with Syncope Caused by a Cardiovascular Disorder**

A man 42 years of age with no history of significant medical problems presents to his physician complaining of "dizzy spells." He has experienced six or seven episodes of dizziness in which he felt like he was "floating" and was about to "pass out." He denies a sense of spinning or illusion of motion but notes that his vision becomes gray at the time of the spells. Each of these lasted only several seconds, and, although he occasionally had to hold onto objects to keep from falling, he had not fallen nor suffered syncope. Friends who witnessed the episodes stated that he looked pale and had him sit to "get his balance."

His past medical history is completely benign, with no history of hearing loss, true vertigo, other neurological symptoms, chest pain, or cardiac symptoms. His physical examination and an electrocardiogram are normal. He is thought to be suffering from "near" syncope and is evaluated for a possible cardiac or neurological cause. A Holter monitor is placed, and a review of the strip reveals a period of arrhythmia with aberrant conduction and 4 seconds of asystole. After further investigation, he undergoes insertion of a cardiac pacemaker and has no further episodes of dizziness.

Discussion

This case illustrates that symptoms that the patient describes as dizziness may not be vestibular in nature but rather some other process (e.g., "near" syncope). Differentiation while taking a history may be challenging and is time consuming. The difficulty is increased further because patients with true vertigo often state that they thought that they were about to "pass out" and may report that they became quite agitated and diaphoretic (due to fear). The astute physician in this case recognized that the history did not include symptoms of an illusion of motion and therefore evaluated the patient for near syncope, probably saving his life.

dysarthria, weakness, and visual changes. Emboli in the carotid or vertebrobasilar systems may result in **transient ischemic attacks**, causing these same symptoms. If an embolus occludes the internal auditory artery, a condition called **labyrinthine apoplexy** results, causing acute vertigo, nausea, vomiting, SNHL, and tinnitus. If atherosclerosis is suspected, evaluation includes carotid imaging studies. Depending on the results of the evaluation, endarterectomy may be indicated. Although the patient's strength may return gradually during the recovery from a stroke, the unsteadiness (caused not only by damage of the labyrinth and CNS but also by decreased proprioception and vision) may be permanent.

Occlusion of the subclavian artery proximal to the branching of the vertebral artery may cause a **subclavian steal** that causes episodic dizziness, headache, vision changes, dysarthria, audible bruit, and a 20–mm Hg difference in blood pressure between both arms and a weakened radial pulse on the steal side. Bypass of the occluded segment may resolve the symptoms. **Wallenberg's syndrome** results from ischemia of the lateral medulla from an occlusion of the posterior inferior cerebellar artery. Vertigo, nausea, vomiting, nystagmus, dysphagia, Horner's syndrome, and ipsilateral vocal cord paralysis are seen with the loss of pain and temperature sensation on the ipsilateral face and the contralateral trunk. A **basilar artery aneurysm** can decrease blood flow to the labyrinth or allow the development of thrombus.

A **vascular loop** is a vascular structure compressing the eighth cranial nerve that can be seen on MRI. This is a diagnosis usually made at surgical exploration (19). Mild compression may produce dizziness and tinnitus, but it is difficult to prove. Surgery during which a synthetic material is placed between the vessel and the eighth cranial nerve sometimes will eliminate the symptoms. Surgical intervention usually includes vestibular nerve section.

Polycythemia, sickle cell anemia, and macroglobulinemia may cause a **hyperviscosity syndrome** that affects the small vessels of the vestibular system. Symptoms include vertigo, hearing loss, and visual disturbance. **Hypoxia** of the labyrinth or CNS may occur with carbon monoxide poisoning, leukemia, lung disease, and severe anemia, resulting in vertigo. **Cardiac arrhythmias** usually cause lightheadedness or presyncope but not true vertigo.

Central Nervous System Diseases

Disorders of the CNS (e.g., **tumors**, **meningitis**, **abscess**) often evoke dizziness or unsteadiness, usually without true vertigo. A neurological examination forms an important part of the work-up for dizziness. If a CNS disorder is suspected, then CT or MRI should be considered.

Epilepsy may be associated with dizziness or vertigo either in the form of an aura preceding a general seizure or as a symptom of temporal lobe

epilepsy. The vertigo ranges in severity and usually is not accompanied by hearing loss; however, the patient may lose consciousness or suffer auditory or visual hallucinations. Management aimed at seizure control usually eliminates episodes of dizziness.

Multiple sclerosis presents with vertigo in 5% to 10% of patients diagnosed and is eventually present in 30% to 40% of all those with the disease (20). Demyelinization can cause dysfunction of the medial longitudinal fasciculus, resulting in internuclear ophthalmoplegia, which is the inability of the medial rectus muscle to return the eye medially after looking laterally. Nystagmus is often present on lateral gaze. Multiple sclerosis also may cause visual disturbances and can injure the long nerve tracts of the spinal cord, causing a loss of proprioception. Because proprioception and visual function contribute to the patient's balance, disturbance of these functions compounds any vestibular problem already present and increases the difficulty of rehabilitation.

Cerebellar disorders may be seen with infection, tumor, vascular disease, toxic ingestion, or aging. Degradation of the connections between the cerebellum and the vestibular system that mediates inhibitory impulses may impair inhibition, resulting in vertigo or dizziness.

Miscellaneous Disorders

Ocular disorders (e.g., decreased acuity, muscle movement, and intraocular pressure) may produce dizziness. Because the visual system is important to spatial orientation, visual disorders intensify symptoms of vestibular disease.

Proprioceptive disorders of the peripheral nervous system caused by alcohol abuse, diabetes mellitus, tabes dorsalis, pernicious anemia, or pellagra may cause imbalance, compounding symptoms of vestibular disease. Posturography may identify a proprioceptive component of the disequilibrium (*see* Fig. 6.8).

Toxic agents that cause vertigo include the same medications that cause hearing loss secondary to hair cell destruction. These medications include aminoglycosides, aspirin, quinine, chemotherapy, and diuretics (21). Audiogram and ENG may be normal early in toxic exposure, but subtle vestibular-system deficits may be detected on sinusoidal harmonic acceleration and the vestibulo-autorotation test. If vestibular function is present on testing, then vestibular exercises help the CNS to compensate. If the drug destroys both vestibular systems, then oscillopsia (i.e., the inability to maintain a stable horizontal visual reference while walking) may occur. This situation presents a difficult problem because the brain is receiving no input with which to generate compensation. ENG shows bilateral hypoactivity on caloric testing. However, if some vestibular activity persists, then rehabilitative vestibular exercises may help (*see* section on Management below).

Cerumen or a foreign body in the external auditory canal may create pressure on the tympanic membrane, causing vertigo. **Eustachian tube dysfunction** caused by allergic rhinitis or upper respiratory infection also may cause dizziness.

Otosclerosis, either of the stapes or the labyrinth, may cause vertigo. It is diagnosed by history, tuning fork tests, and audiometry. When the stapes is involved, a stapedectomy may be performed if the patient does not have active Meniere's disease. If the otosclerosis involves the labyrinth, oral sodium fluoride may halt the progression of disease.

Motion sickness is due to unaccustomed periodic movements and causes dizziness, nausea, and vomiting. The absence of compensation by vision or proprioception worsens the symptoms. An example is a ship passenger whose *mal de mer* becomes worse when he goes below deck and loses a visual reference (e.g., the horizon, the surface of the sea). Occasionally, after a prolonged voyage, the patient may experience recurrent sensations of imbalance on solid land for a period of months to years, a condition called ***mal de debarquement*** syndrome (22). Motion sickness is treated with antihistamines, diazepam, scopolamine, and other vestibular suppressants.

The natural process of **aging** can be accompanied by dizziness and impairment of balance (23). The connections between the different areas of the vestibular system weaken with age, and the hair cells slowly atrophy. The receptors within the vasculature may decrease in sensitivity, causing postural hypotension on rapid position change. The patient learns to change positions more slowly. Additionally, the proprioceptive and visual systems decrease in efficiency over the years.

Psychogenic vertigo is a diagnosis of exclusion. These patients present with an atypical or bizarre story, hyperventilation, an impending lawsuit, or symptoms of other psychiatric disorders. The most useful test for distinguishing these patients is posturography.

Management

The treatment of vertigo begins only after an appropriate history interview, physical examination, and directed evaluation. Most conditions that produce dizziness are not emergencies, usually resolve spontaneously, and can be evaluated on an outpatient basis. Causes that may need more immediate treatment or referral are listed in the section on Danger Signs below.

In general, acute cases with intolerable symptoms call for **vestibular suppression** using medications that blunt both the vestibular system and the CNS (e.g., oral meclizine 12.5–25.0 mg four times daily). Oral diazepam 2.5 mg three times daily helps vestibular suppression. Antiemetics (e.g., droperidol, odansetron [Zofran]), anticholinergics, or both assist in controlling the

symptoms. Vasodilators (e.g., hydralazine, niacin, histamine, carbogen) may help relieve dizziness when a vascular disorder is suspected.

The patient should be counseled about **lifestyle changes** that include discontinuing smoking, avoiding alcohol and caffeine, restricting salt intake, and reducing life stress (12).

Vestibular exercises include maneuvers that elicit dizziness, gradually desensitizing the patient. For example, if a head turn to the right elicits dizziness, then the patient performs repeated head turns to the right until the dizziness begins, after which the patient stops and rests until the symptoms fade. The same process is repeated multiple times, and the exercises then continue with other head turns and body positions. Vestibular-suppressant medication will retard central compensation and should be used sparingly in patients undergoing vestibular exercises.

If medical management fails, **surgical treatment** can be offered. Some surgical procedures (e.g., endolymphatic sac decompression, shunting for Meniere's disease) can preserve hearing. Destructive procedures (e.g., vestibular nerve section [which can preserve hearing], labyrinthectomy [when no serviceable hearing exists]) are effective in controlling vertigo. Recently, it has been found that aminoglycoside injected experimentally into the middle ear destroys the hair cells responsible for vertigo, evidently sparing the cells responsible for hearing.

Danger Signs

Danger signs in the evaluation of patients with dizziness include the following:

- **Herpes zoster oticus (Ramsey–Hunt syndrome) with facial nerve paralysis:** requires antiviral treatment
- **Labyrinthitis (suppurative or serous):** often requires admission for control of progression and may need surgical drainage
- **Fungal infection of the labyrinth:** occurs primarily in immunocompromised individuals and requires surgical debridement and antifungal therapy
- **Temporal bone fracture with facial nerve paralysis:** may need surgical decompression of the bony canal of the facial nerve
- **Trauma accompanied by vertigo (with or without temporal bone fracture):** may need surgical exploration of the stapes
- **Trauma with unsteadiness (with or without temporal bone fracture):** may represent a subdural hematoma and may require treatment
- **Sudden vertigo and asymmetrical hearing loss:** may indicate an acoustic neuroma

- **Lightheadedness with abnormal blood glucose:** may indicate diabetes mellitus or hypoglycemia
- **Dizziness with recent onset of short-lived neurological symptoms:** may need carotid imaging and endarterectomy, especially if carotid bruits are present
- **Dizziness and palpitations:** may indicate a cardiac arrhythmia
- **Dizziness and nonspecific signs of infection and meningismus:** may indicate a CNS infection that requires treatment

Summary

Patients complaining of dizziness may have vertigo of vestibular origin, or they may be suffering from the lightheadedness or disequilibrium caused by disorders of other systems. Determining the origin of dizziness is the starting point of effective treatment.

REFERENCES

1. **Dohlman GF.** The attachment of the cupulae, otolith, and tectorial membranes to the sensory cell area. *Acta Otolaryngol.* 1971;71:89–105.
2. **McCabe BF.** The quick component of nystagmus. *Laryngoscope.* 1988;98:502–6.
3. **Fluur E.** Vestibular compensation after labyrinthine destruction. *Acta Otolaryngol.* 1960;52:367–74.
4. **Rubin W.** Nystagmography: terminology, technique, and instrumentation. *Arch Otolaryngol.* 1968;87:266–71.
5. **Stennerson RL, Van de Water SM, Systma WH, et al.** Central vestibular findings on electronystagmography. *Ear Hear.* 1986;7:176–81.
6. **Rubin W.** How do we use state-of-the-art vestibular testing to diagnose and treat the dizzy patient? An overview of vestibular testing and balance system integration. *Neurol Clin.* 1990;8:225–34.
7. **Paparella MM, Mancini F.** Vestibular Meniere's disease. *Otolaryngol Head Neck Surg.* 1985;93:148–51.
8. **Driscoll CLW, Kasperbauer JL, Facer GW, et al.** Low-dose intratympanic gentamicin and the treatment of Meniere's disease: preliminary results. *Laryngoscope.* 1997;107:83–9.
9. **Nadol JB.** Vestibular neuritis. *Otolaryngol Head Neck Surg.* 1995;112:162–72.
10. **Epley JM.** Positional vertigo related to semicircular canalithiasis. *Otolaryngol Head Neck Surg.* 1995;112:154–61.
11. **Lempert T, Tiel-Wilck K.** A positional maneuver for treatment of horizontal-canal benign positional vertigo. *Laryngoscope.* 1996;106:476–8.
12. **Cawthorne T.** The physiological basis for head exercises. *J Chart Soc Physiother.* 1944;106–7.
13. **Wall C, Rauch SD.** Perilymph fistula pathophysiology. *Otolaryngol Head Neck Surg.*

1995;112:145–53.

14. **Podoshin L, Fradis M, Ben-David J, et al.** Perilymph fistula: the value of diagnostic tests. *J Laryngol Otol.* 1994;108:560–3.
15. **Harris JP, Ryan AF.** Fundamental immune mechanisms of the brain and inner ear. *Otolaryngol Head Neck Surg.* 1995;112:639–53.
16. **Cogan DG.** Syndrome of nonsyphilitic interstitial keratitis and vestibuloauditory symptoms. *Arch Ophthalmol.* 1945;33:144.
17. **Sidorov JE, Benkovic GW, Greenfield LS, et at.** Metabolic abnormalities and vertigo. *Arch Intern Med.* 1987;147:197.
18. **Grad A, Baloh RW.** Vertigo of vascular origin. *Arch Neurol.* 1989;46:281–4.
19. **McCabe BF, Gantz BJ.** Vascular loop as a cause of incapacitating dizziness. *Am J Otol.* 1989;10:117–20.
20. **Schumacher GA.** Demyelinating diseases as a cause for vertigo. *Arch Otol.* 1967; 85:93–4.
21. **Fee WEJ.** Aminoglycoside ototoxicity in the human. *Laryngoscope.* 1980;24(Suppl): 1–19.
22. **Brown JJ, Baloh RW.** Persistent mal de debarquement syndrome. *Am J Otolaryngol.* 1987;8:219–22.
23. **Sloane PD, Balch RW, Honrubia V.** The vestibular system in the elderly. *Am J Otolaryngol.* 1989;10:422–9.

SUGGESTED READINGS

Drachman DA. A 69-year-old man with chronic dizziness. *JAMA.* 1998; 280:2111–8.

This article is one of the Clinical Crossroads series, detailing the evaluation and management of a man suffering from persistent dizziness.

Fitzgerald DC. Head trauma: hearing loss and dizziness. *J Trauma.* 1996; 40:488–96

This article discusses the connections between head trauma and vestibulocochlear injury, including mechanisms of injury and prognosis.

Lempert T, Tiel-Wilck K. A positional maneuver for treatment of horizontal-canal benign positional vertigo. *Laryngoscope.* 1996;106:476–8.

This article describes in detail the positional maneuvering for treating benign positional vertigo.

Ruckenstein MJ. A practical approach to dizziness: questions to bring vertigo and other causes into focus. *Postgrad Med.*1995; 97:70–81.

This article contains a broad overview of the varied causes of dizziness, with suggestions for focusing the history and physical examination on the most likely causes in each patient.

Sloane PD, Balch RW, Honrubia V. The vestibular system in the elderly. *Am J Otolaryngol.* 1989;10:422–9.

This article details some of the changes that take place in the vestibular system as the patient ages and how these affect the clinical presentation and pathophysiology.