Deficiency of the superior semicircular canal

Gerard J. Gianoli, MD, FACS

Deficiency of the superior semicircular canal (SSCD) has been defined as the absence of bone overlying the superior semicircular canal (SSC) toward the middle fossa dura. SSCD has recently been reported to be associated with a syndrome of sound- or pressure-induced vertigo and oscillopsia. The vertical–torsional nystagmus induced by sound in these patients has been identified to correlate with the affected SSC. High-resolution computed tomograph scan and middle fossa exploration have corroborated these findings. Repair or occlusion of the SSC has resulted in resolution or improvement of symptoms. SSCD should be evaluated in patients who have sound- or pressure-induced vertigo and in patients who have been diagnosed with atypical Meniere or perilymphatic fistula. Curr Opin Otolaryngol Head Neck Surg 2001, 0:000–000 © 2001 Lippincott Williams & Wilkins, Inc.

AU1 Baton Rouge, Louisiana, USA.

Correspondence to Gerard J. Gianoli, MD, FACS, 17050 Medical Center Drive, Suite #315, Baton Rouge, LA 70816, USA; e-mail: gianoli@bellsouth.net

Current Opinion in Otolaryngology & Head and Neck Surgery 2001, 0:000–000

Abbreviations

CT	computed tomograph
SSC	superior semicircular canal
SSCD	deficiency of the superior semicircular canal

ISSN 1068-9508 © 2001 Lippincott Williams & Wilkins, Inc.

Deficiency of the superior semicircular canal: symptoms and vestibular findings

Deficiency of the superior semicircular canal (SSCD) has been defined as the absence of bone overlying the superior semicircular canal (SSC) toward the middle fossa dura (Fig. 1). SSCD has recently been reported to be F1 associated with a syndrome of sound- or pressure-induced vertigo. Many of these patients had been previously suspected of having oval or round window perilymphatic fistulas, or Meniere disease. Minor *et al.* [1••] AU2 initially reported on eight patients who had evidence of SSCD on computed tomograph (CT) imaging. These eight patients exhibited symptoms of vertigo or oscillopsia elicited by certain sounds or activities that increased intracranial or middle ear pressure (valsalva, coughing, sneezing, autoinsufflation, *etc.*). Seven of the eight patients demonstrated torsional eye movements in response to sound or pressure stimuli. The direction of the torsional eye movements strongly implicated direct stimulation of the SSC in the affected ear. Sound, positive pressure in the ear canal, and valsalva with pinched nostrils (autoinsufflation) resulted in nystagmus with the slow phase upward and the superior pole of the eye torquing away from the affected ear. Valsalva against a closed glottis, jugular venous compression, or negative pressure in the ear canal resulted in nystagmus with the slow phase directed upward and the superior pole of the eye torquing towards the affected ear.

It was hypothesized that the absence of bone overlying the SSC, resulting in a third mobile window, allowed deflection of the SSC cupula from pressure transmitted from either the intracranial space, or the round or oval windows. Two of these patients underwent middle fossa exploration, which confirmed the presence of SSCD. The SSCD was plugged with a mixture of fascia, bone dust, and fibrin glue in both cases. Although both patients had complete resolution of Tullio phenomenon and improvement in vestibular symptoms postoperatively, nystagmus continued to be reproduced by valsalva in one patient, and the other patient had a positive fistula test after the 4th postoperative month. In both surgical explorations, the tegmen was noted to have "areas of erosion."

Brantberg *et al.* [2•] reported three patients with CT imaging consistent with SSCD who had symptoms of sound- or pressure-induced vertigo. All three patients demonstrated abnormally large vestibular-evoked myo-

Figure 1. Middle fossa approach

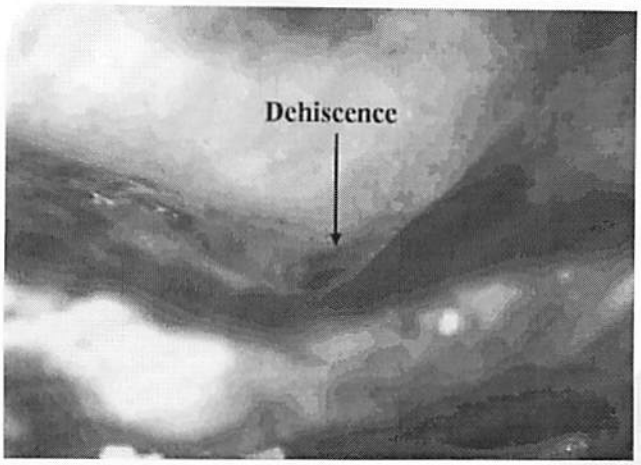

Intraoperative view of deficiency of the superior semicircular canal.

genic potentials in response to sound stimuli in the frequency range of 0.5 to 1 kHz. In addition, torsional eye movements were noted in response to the sound stimuli analogous to SSC stimulation. One patient underwent middle fossa exploration with confirmation and plugging of SSCD. Postoperatively, he noted improvement but not elimination of symptoms. One patient presented with the symptom of pulsatile tinnitus and the feeling that his left eye moved in concert with his pulse.

Mong *et al.* [3•] reported a patient with symptoms of sound- or pressure-induced vertigo that began after a coughing spell. She also noted tinnitus, aural fullness, and vertigo with quick head movements. Electronystagmogram (ENG) fistula testing demonstrated no evidence AU3 of objective nystagmus, although the patient experienced vertigo with pressure applied to the affected ear. Middle ear exploration with repair of oval and round windows failed to relieve her symptoms. CT scan demonstrated SSCD of the affected ear. She declined middle fossa exploration.

Minor [4•] updated his previously reported series with 17 patients who had symptoms of SSCD and CT evidence of SSCD. Three patients, in addition to the two patients previously described, had undergone exploration for SSCD. In these cases, one had canal plugging as previously described and the other two had resurfacing of the SSCD with temporalis fascia and a cortical bone graft. All five of the patients have had improvement of symptoms. One patient had recurrence of symptoms that required revision surgery, and two patients (one with the plugging procedure, one with the resurfacing procedure) developed signs of vestibular hypofunction postoperatively. All five patients have had persistence of pressure-induced symptoms, despite resolution or improvement in their other symptoms.

Smullen *et al.* [5•] reported three patients with SSCD with varied presentations. One patient presented with Meniere syndrome, one with pressure-induced vertigo, and one with no vestibular symptoms. The one patient who had no vestibular symptoms underwent middle fossa craniotomy for repair of an encephalocele, and SSCD was noted intraoperatively. The other two patients had resolution of their vestibular symptoms with repair of SSCD using a cortical bone graft and hydroxyapatite bone cement. AU4

Watson *et al.* [6•] reported on four patients presenting with Tullio phenomenon. In five ears of four patients, torsional nystagmus occurred in response to low-frequency sound stimulation. Vestibulocollic testing AU5 demonstrated abnormally low thresholds (55-65 dB nHL) for the affected ears and normal thresholds for the three unaffected ears. CT scan demonstrated SSCD in all the affected ears. Additionally, contralateral SSCD was noted in two asymptomatic ears. No surgical explorations were reported with this study.

Ostrowski *et al.* [7••] reported on a single patient with right SSCD identified by CT imaging who had Tullio phenomenon. This patient underwent vector analysis of nystagmus with sound stimulation (maximal response with 1250 Hz, 95 dB) of the affected ear. Amplitude of nystagmus was noted to be 1-7 d/s torsional, 1-5 d/s ver- AU6 tical and less than 1.5 d/s horizontal, producing a counterclockwise and downward nystagmus with stimulation of the right ear. Using vector analysis of the known nystagmus patterns of the semicircular canals identified the right superior semicircular canal as the source of the nystagmus. Strupp *et al.* [8•] also reported a single case of SSCD, demonstrated on CT, with Tullio phenomenon. Vector analysis of sound-induced vertigo also suggested the SSC as the source of nystagmus in their patient. Cremer *et al.* [9•] analyzed eye movements in 11 patients who had sound- or pressure-induced vertigo and CT scan evidence of SSCD in the affected ear. Slow phase eye movements during nystagmus produced by sound stimulation were upward and torsional, implicating the superior semicircular canal as the source of nystagmus rather than the utricle.

Brantburg *et al.* [10•] recently updated their experience, reporting on the findings of eight patients with SSCD. All patients reported pressure-induced vertigo, and some patients noted pulse synchronous tinnitus and gaze instability with head movements. A small conductive loss on audiometry with normal stapedial reflexes was also noted in some patients. Sound-induced nystagmus produced vertical–torsional nystagmus, as others have reported, implicating the superior semicircular canal. One patient had superior canal-related positioning nystagmus. Vestibular-evoked myogenic potentials demonstrated vestibular hypersensitivity to sound in the af-

fected ears. A coronal 1-mm slice CT scan confirmed the finding of SSCD in all patients. Two patients underwent a transmastoid approach to plug the superior semicircular canal. Both patients have had resolution of their pressure-induced symptoms postoperatively.

Incidence

Carey *et al.* [11••] studied 1000 vertically sectioned specimens from 596 adult temporal bones and 36 specimens from 20 infants to determine the incidence and possible cause of SSCD. Complete absence of bone over the SSC was noted in 0.5% of adult temporal bones. An additional 1.4% were noted to have thin bony covering (< 0.1 mm), which was significantly less than the values obtained from the control specimens. These prevalence numbers are likely to be an underestimation of the true prevalence, because 3% of the specimens were excluded because of defects over the bone and dura. These specimens were removed from analysis because it could not be determined if the bone had been avulsed at the time of processing; however, a specimen with SSCD would have this appearance if the dura had been stripped (If all of these specimens had thin or dehiscent bone, the prevalence of SSCD and thinned SSC bone would approach 5%). The infant temporal bones demonstrated uniformly thin bone over the SSC with progressive thickening until 3 years of age. Defects were typically bilateral, and a frequent finding was SSCD at the superior petrosal sinus. They theorized that SSCD was a developmental aberration that required a second event (*ie*, trauma or sudden pressure change) for the disruption of thin bone covering the SSC and the development of vestibular symptoms. This theory, however, would not explain how someone with SSCD could be asymptomatic and, if this is a developmental aberration, why symptoms are not present in childhood.

Roberto *et al.* [12] examined the temporal bones of dogs after tetracycline staining at 10, 25, and 50 days of age. Light microscopic examination revealed that endochondral and endosteal bone is deposited postnatally at the superior semicircular and horizontal semicircular canals. Bone deposition decreases with age—earlier at the endosteum than at the endochondral bone. This result is in agreement with the findings of progressive thickening of SSC bone in human fetal temporal bones by Carey *et al.* [11••].

Imaging

Although SSCD is defined by history and physical findings, radiographic imaging has been used to confirm the presence of SSCD. High-resolution coronal CT scan has been the imaging modality of choice (Fig. 2); however, F2 the size of the bony deficiency approaches the standard 1-mm slice thickness of most scanners. Consequently, the margin of error—false-positive or false-negative scans—is magnified. Accuracy of imaging is improved by the thinner slice thickness (0.5 mm) used in newer scanners; however, false-positive scans may still occur because of averaging artifact. In addition, the author has identified several patients who have SSCD and are asymptomatic (Gianoli and Smullen, Superior semicircular canal dehiscence: prevalence and symptoms, Paper presented at the Annual Meeting of the American Academy of Otolaryngology–Head and Neck Surgery, New Orleans, 1999). Consequently, the finding of SSCD on a AU7 CT scan does not necessarily mean causation. The CT findings should be carefully correlated with history and vestibular findings.

The dehiscent middle fossa

Sutton *et al.* (Dehiscent middle cranial fossa: findings associated with superior semicircular canal dehiscence on high resolution computed tomography, Paper presented at the Annual Meeting of the American Society of Neuroradiology, Atlanta, 2000) recently presented a radio-

Figure 2. High-resolution coronal computed tomograph scan of a normal superior semicircular canal and a superior semicircular canal with bony deficiency

(A) Normal superior semicircular canal. **(B)** Superior semicircular canal dehiscence.

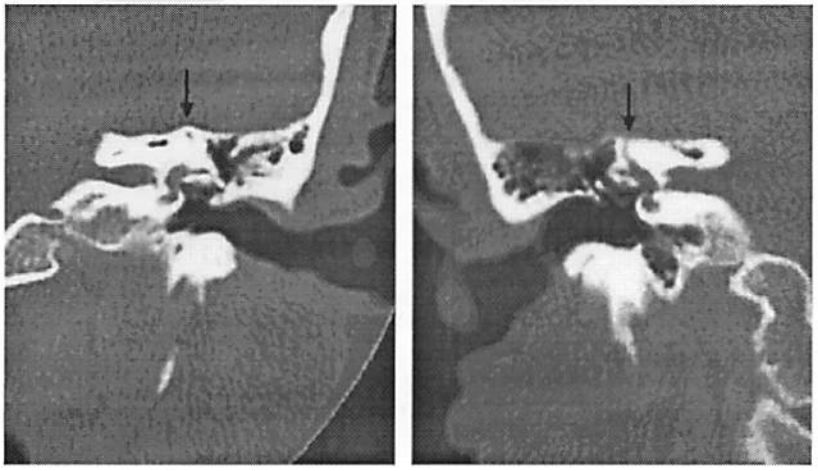

graphic series of patients with SSCD, finding a high incidence of associated anatomic abnormalities of the middle cranial fossa. These abnormalities include dehiscence of the geniculate ganglion, tegmen defects, temporal lobe encephaloceles, and cerebrospinal fluid leaks. These abnormalities, along with SSCD, seem to suggest a generalized deficiency of bone formation/deposition of the middle cranial fossa floor or a dehiscent middle fossa.

Bony dehiscence of the geniculate ganglion in adults has been investigated by several authors with the incidence ranging from 5 to 15% [13–15]. Dehiscence of the geniculate ganglion was noted in 53% (25/47) of this survey of temporal bone CT scans that had SSCD (Fig. 3). F3 The prevalence of this finding may be high because of averaging artifact; however, the findings in the radiographic series correlate well with reported surgical findings.

Declau *et al.* [16] investigated the embryologic development of the bony covering of the facial canal by examining human fetuses, with both light and scanning electron microscopic evaluation. They identified three distinct stages of bony facial canal development *in utero*. The areas covered by intramembranous bone were found to be most susceptible to persistent dehiscence in adulthood. Additionally, the labyrinthine segment and geniculate ganglion were found to remain dehiscent toward the middle fossa dura throughout embryologic development, developing a bony covering in early childhood. The high incidence (53%) of persistent geniculate ganglion dehiscence among patients with SSCD suggests a developmental anomaly of intramembranous bone formation of the middle cranial fossa during early childhood.

Previous reports of randomly selected temporal bones have identified tegmen dehiscences in 0 to 34% of specimens, with most authors finding an incidence of 20 to 22% [17–21]. Sutton *et al.* (Dehiscent middle cranial fossa: findings associated with superior semicircular canal dehiscence on high resolution computed tomography, Paper presented at the Annual Meeting of the American Society of Neuroradiology, Atlanta, 2000) identified multiple tegmen defects among 81% of the temporal bone CT scans in SSCD patients (Fig. 4). This finding could F4 represent an overrepresentation of the prevalence of tegmen defects because of averaging artifact of CT imaging; however, Merchant and McKenna [22] noted, in their recently published experience with management of multiple spontaneous tegmen defects, that imaging studies (CT scan) generally underestimate the number of tegmen defects. They felt that this finding resulted from the generally small size of the multiple defects and the inability of CT to differentiate a true defect from a thin bony plate. Additionally, the CT findings in SSCD patients are in concordance with surgical reports.

The prevalence of tegmen defects in SSCD patients is much higher than any of the studies of unselected temporal bones (0–34%). Geniculate ganglion dehiscence is also much more common in the SSCD population (53%) compared with studies of unselected temporal bones (5–15%). The presence of multiple tegmen defects and geniculate ganglion dehiscence appears to be strongly associated with SSCD. This finding also suggests that SSCD, geniculate ganglion dehiscence, and tegmen de-

Figure 3. High-resolution coronal computed tomograph scan of geniculate ganglion with bone coverage and with bone absence on the middle fossa overlying the geniculate ganglion in a patient with deficiency of the superior semicircular canal

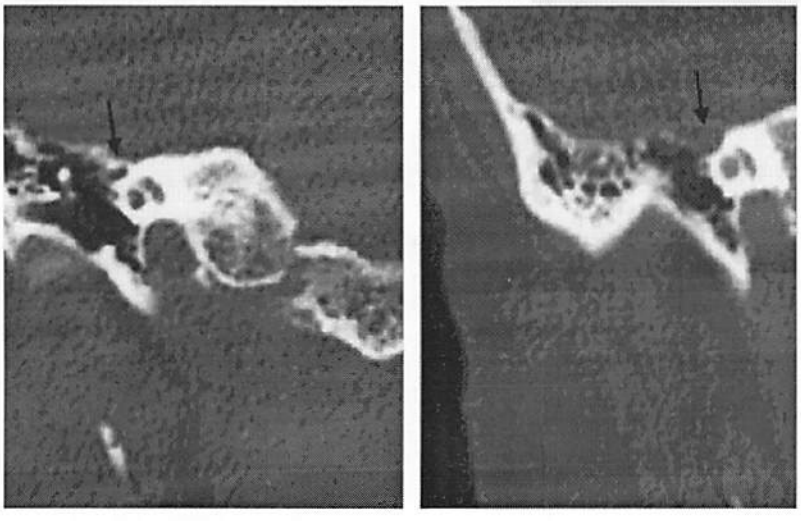

(A) Normal geniculate ganglion bony covering. **(B)** Dehiscence of geniculate ganglion bony covering.

Figure 4. High-resolution coronal computed tomograph scan in a patient with deficiency of the superior semicircular canal who also has multiple tegmen dehiscences and an encephalocele

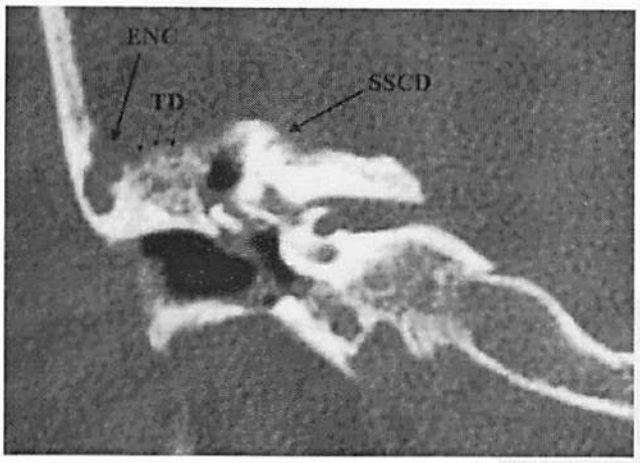

This patient was also identified to have an associated cerebrospinal fluid leak. ENC, encephalocele; SSCD, deficiency of the superior semicircular canal; TD, tegmen dehiscence.

fects may have a common etiology. The final bony covering at the middle fossa surface of each of these structures is not complete until early childhood. These findings further suggest failure of bony deposition of the middle cranial fossa floor during early childhood.

Surgical repair

There have been 38 reported cases of SSCD identified by CT scan and clinical criteria [1••,2•,3•,4•,5•,6•,7••,8•,9•,10•]. Nine of these patients underwent middle fossa exploration with confirmation of SSCD. These AU8 SSCs were occluded or repaired with improvement in their symptoms. Two patients have had transmastoid occlusion of the superior semicircular canal with resolution of symptoms. Repair has been accomplished by occlusion of the SSC or repair of the area of bony deficiency. Repair has been accomplished with use of fascia, fibrin glue, calvarial grafts, and hydroxyapatite cement. The author favors a middle fossa approach with repair using calvarial bone covering the SSCD and sealing around the calvarial graft with hydroxyapatite cement. This approach has the advantage of preserving SSC function and eliminating the minimal risk of violating the inner ear required by occlusion (through the middle fossa or transmastoid). It also has the advantage of definitively demonstrating the repair postoperatively by CT scan (Fig. 5). F5

Care should be taken in the region of the geniculate ganglion, because of the high rate of geniculate ganglion bony dehiscence in these patients. The author has witnessed a few delayed facial palsies that have occurred approximately 1 week after surgery. All of these facial palsies have resolved using valacyclovir and prednisone. Because of the anatomic association of tegmen defects, these patients are theoretically at higher risk for postoperative cerebrospinal fluid leak; however, in practice, this finding has not been noted.

Conclusions

Patients with the symptoms of vertigo induced by certain sounds or activities that alter intracranial or middle ear pressure (coughing, nose blowing, straining, *etc.*) should be evaluated for SSCD. Many patients with SSCD have previously been suspected to have perilymphatic fistulas (oval or round window) or atypical Meniere disease. Typically, SSCD patients will have a vertical torsional nystagmus in response to sound or pressure stimuli (fistula test) and increased sensitivity on vestibular-evoked myogenic potential testing. High-resolution CT will confirm the finding of SSCD and will often demonstrate

Figure 5. Preoperative and postoperative high-resolution computed tomograph scans demonstrating repair of a deficiency of the superior semicircular canal with maintenance of superior semicircular patency after surgery

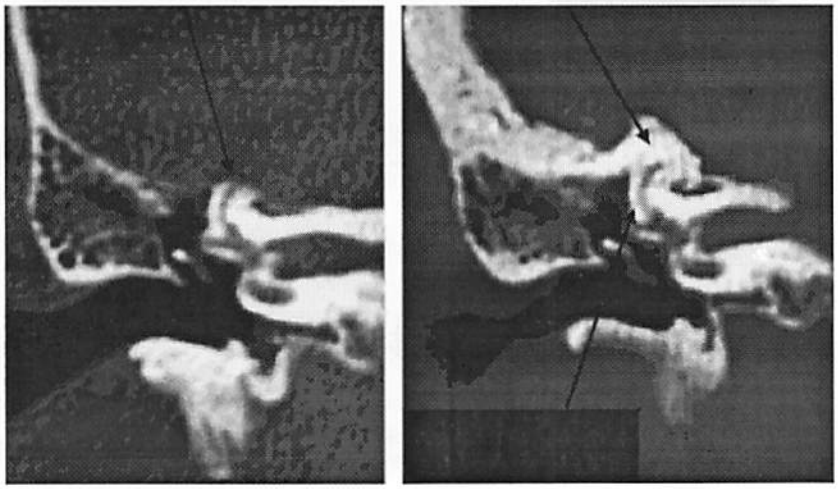

A calvarial bone graft had been placed over the superior semicircular canal and hydroxyapatite cement was used to seal around the graft. Hydroxyapatite cement was also used to seal the craniotomy site. **(A)** Superior semicircular canal dehiscence before repair (arrow). **(B)** After repair with calvarial bone and hydroxyapatite bone cement (arrowhead). Patency of the superior semicircular canal was maintained (arrow).

associated middle fossa anomalies, such as dehiscences of the tegmen and geniculate ganglion. Surgical repair or occlusion of the SSC through a middle fossa or transmastoid approach has resulted in improvement or resolution of the sound- and pressure-related symptoms.

References and recommended reading

Papers of particular interest, published within the annual period of review, have been highlighted as:
• Of special interest
•• Of outstanding interest

AU9 1 •• Minor LB, Solomon D, Zinreich JS, et al.: Sound- and/or pressure-induced vertigo due to bone dehiscence of the superior semicircular canal. Arch Otolaryngol Head Neck Surg 1998, 124:249–258.

2 • Brantberg K, Bergenius J, Tribukait A: Vestibular-evoked myogenic potentials in patients with dehiscence of the superior semicircular canal. Acta Otolaryngol 1999, 119:633–640.

3 • Mong A, Loevner LA, Solomon D, et al.: Sound- and pressure-induced vertigo associated with dehiscence of the roof of the superior semicircular canal. Am J Neuroradiol 1999, 20:1973–1975.

4 Minor LB: Superior canal dehiscence syndrome. Am J Otol 2000, 21:9–19.

5 • Smullen JL, Andrist EC, Gianoli GJ: Superior semicircular canal dehiscence: a new cause of vertigo. J Louisiana State Med Soc 1999, 151:397–400.

6 • Watson SRD, Halmagyi M, Colebatch JG: Vestibular hypersensitivity to sound (Tullio phenomenon): structural and functional assessment. Neurology 2000, 54:722–728.

7 •• Ostrowski VB, Byskosh A, Hain TC: Tullio phenomenon with dehiscence of the superior canal. Otol Neurotol 2001, 22:61–65.

8 • Strupp M, Eggert T, Straube A, et al.: "Inner perilymph fistula" of the anterior semicircular canal. A new disease picture with recurrent attacks of vertigo. Nervenarzi 2000, 71:138–142.

9 • Cremer PD, Minor LB, Carey JP, et al.: Eye movements in patients with superior semicircular canal dehiscence syndrome align with the abnormal canal. Neurology 2000, 55:1833–1841.

10 • Brantburg K, Bergenius J, Mendel L, et al.: Symptoms, findings and treatment in patients with dehiscence of the superior semicircular canal. Acta Otolaryngol 2001, 121:68–75.

11 •• Carey JP, Minor LB, Nager GT: Dehiscence or thinning of the bone overlying the superior semicircular canal in a temporal bone survey. ED1

12 Roberto M, Favia A, Lozupone E: Postnatal bone growth in the semicircular canals of the dog. Italian J Anat Embryol 198, 103:27–34.

13 House WF, Crabtree JA: Surgical exposure of the petrous portion of the 7th nerve. Arch Otolaryngol 1965, 81:506–507.

14 Maquet J: Congenital malformations and middle ear surgery. J Roy Soc Med 1981, 74:119–128.

15 Rhoton AL, Pulec JL, Hall GM, et al.: Absence of bone over the geniculate ganglion. J Neurosurg 1968, 28:48–53.

16 Declau F, Jacob W, Montoro S, et al.: Dehiscence of the facial canal: developmental aspects. Int J Pediatr Otorhinolaryngol 1991, 21:21–32.

17 Ahren C, Thulin CA: Lethal intracranial complications following inflation in the external auditory canal in the treatment of serous otitis media due to defects in the petrous bone. Acta Otolaryngol (Stockh) 1965, 60:407–421.

18 Lang DV: Macroscopic bony deficiencies of the tegmen tympani in adult temporal bones. J Laryngol Otol 1983, 97:685–688.

19 Kapur TR, Bangash W: Tegmental and petromastoid defects in the temporal bone. J Laryngol Otol 1986, 100:1129–1132.

20 Ferguson BJ, Wilkins RH, Hudson W, et al.: Spontaneous CSF otorrhea from tegmen and posterior fossa defects. Laryngoscope 1986, 96:635–644.

21 Jahrsdoerfer RA, Richtsmeier WJ, Cantrell RW: Spontaneous CSF otorrhea. Arch Otolaryngol 1981, 107:257–261.

22 Merchant SN, McKenna MJ: Neurotologic manifestations and treatment of multiple spontaneous tegmental defects. Am J Otol 2000, 21:234–239.