Chapter 16
Pathophysiology and Diagnosis of Superior Canal Dehiscence

Gerard J. Gianoli and James Soileau

Introduction

SCD can be defined as both an anatomic anomaly found on CT scan and/or at surgical exploration (Figs. 16.1 and 16.2) and as a syndrome that frequently accompanies this anatomic deviation. When SCD was first described in 1998 [1], it was felt to be a rare disorder. However, over the past 20 years, it has been recognized more frequently as the varying clinical presentations have been elucidated. SCD has been called the great otologic mimicker. This is due to the myriad of clinical presentations that may be identical to other major otologic disorders such as patulous eustachian tube, otosclerosis, Meniere's disease, perilymph fistula, acute vestibular neuritis, and vestibular migraine [2]. This variety of presentations may lead to a delay in diagnosis, misdiagnosis, and in some cases inappropriate treatment. The correct diagnosis is important since relief of symptoms can be attained among the majority of SCD patients with appropriate treatment.

Included in the spectrum of SCD is the asymptomatic patient, which presumably includes all SCD patients prior to the onset of their symptoms. There are many patients with anatomic dehiscence of the superior canal that have no symptoms. Due to this, simply noting the anatomic presence of SCD does not signify causation for the patient's symptomatology. It has been recognized since the initial description of the problem in 1998 that a "second event" is suspected to be the root cause of the onset of the symptoms of SCD. The leading suspected "second events" are head trauma and major pressure-altering events – affecting middle ear or intracranial pressure. This is the presumed reason why SCD syndrome is seen rarely in the pediatric population.

G. J. Gianoli (✉)
The Ear and Balance Institute, Covington, LA, USA

Department of Otolaryngology, Tulane University, New Orleans, LA, USA

J. Soileau
The Ear and Balance Institute, Covington, LA, USA

S. Babu et al. (eds.), *Diagnosis and Treatment of Vestibular Disorders*,
https://doi.org/10.1007/978-3-319-97858-1_16

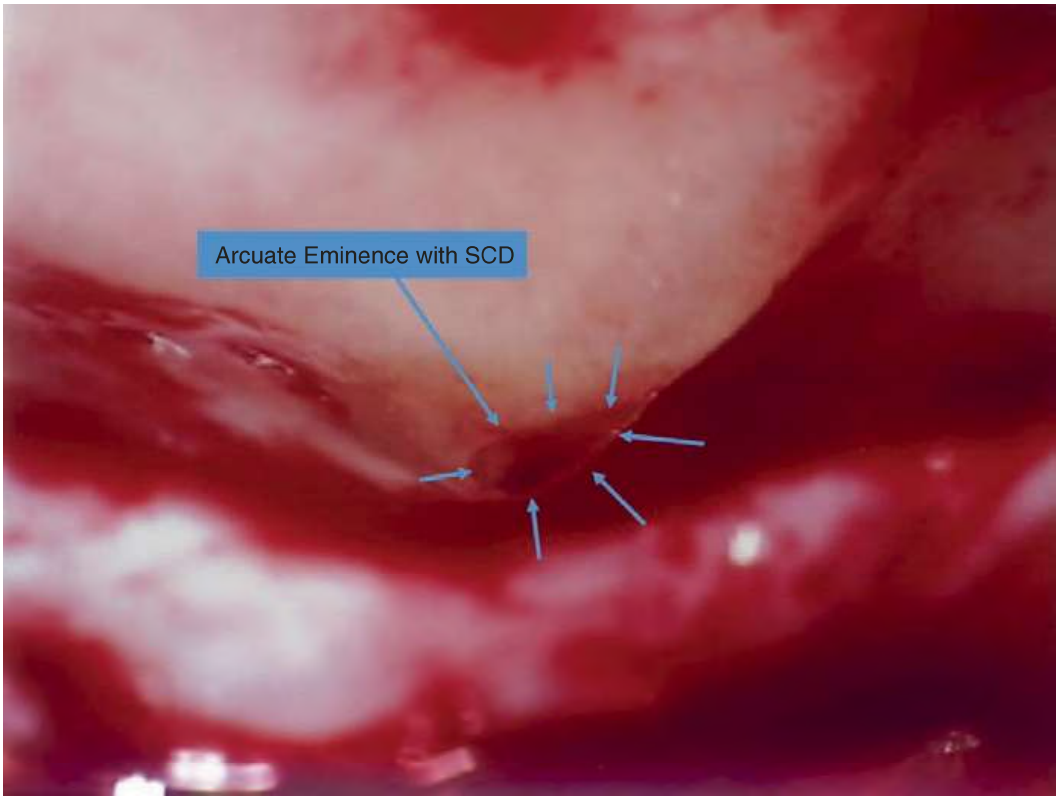

Fig. 16.1 Intraoperative view of the middle fossa floor exploration demonstrating SCD at the arcuate eminence

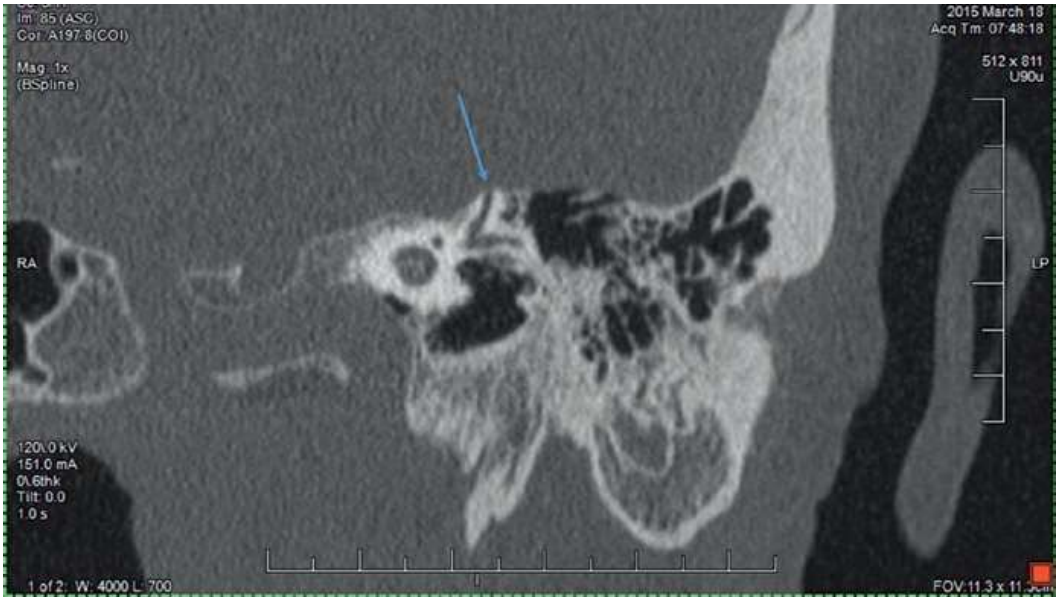

Fig. 16.2 CT scan demonstrating SCD

Incidence and Etiology

An anatomic dehiscence of the bone overlying the superior semicircular canal at its interface with the middle cranial fossa dura has been proposed to be a developmental abnormality [1]. In utero between 32 and 40 weeks' gestation, which is beyond the time of the labyrinth reaching adult size, the incidence of SCD approaches 89% [3]. The bone overlying the middle fossa floor (or, conversely, covering the tegmen mastoideum and tegmen tympani) thickens progressively in utero and throughout early childhood, such that a 1-year-old with CT findings of SCD may see it "disappear" by the time they are 3 or 4 years old [4]. Sugihara and colleagues [5] in a review of 1006 temporal bone CT scans demonstrated progressive thickening of superior semicircular canal (SSC) bone throughout the first 8 years of life with a concomitant progressive lower incidence of SCD during that time period. At this age, the incidence of the anatomic finding of SCD is believed to be relatively stable, rendering 0.5% with frank dehiscence and 1–2% of the general population with exceedingly thin bone (≤0.1 mm thickness) in this area [6]. Either frank dehiscence or thin bone of the superior semicircular canal (SSC) theoretically places these individuals at risk for developing SCD syndrome later in life.

The thickness of the calvarium and the area of the middle fossa floor overlying the SSC very slowly thins throughout the course of our lives [7]. This has been submitted as evidence pointing toward an acquired etiology for SCD as opposed to the "congenital or developmental etiology" [7]. This is undoubtedly true for some SCD patients but is unlikely to account for the majority of SCD patients. Additionally, a small number of patients have been identified who acquire SCD from erosive processes such as arachnoid granulations, cholesteatomas, other tumors, and fractures. The authors have also identified a few cases of iatrogenic SCD acquired due to skull base approaches for tumor resections. More recently, the CDH23 gene (associated with Usher syndrome and non-syndromic hearing loss) has been found to be a genetic risk factor for the development of SCD [8].

The prevalence of SCD has been found to be much higher in series of analyzed CT scans than on temporal bone histology. Carey et al. identified complete absence of bone over the superior canal histologically in 0.5% of 1000 vertically sectioned adult temporal bones [6]. There was an additional 1.4% with very thin (≤0.1 mm) bone covering the superior canal. Added together, the prevalence of thin or dehiscent superior canals approached 2%. This study also reported that 50% of the SCD cases had bilateral involvement. Carey and colleagues [6] also analyzed 36 infant temporal bones and concluded that the thickness of the bone overlying the superior canal was consistently thin. The thickness of the bone covering the superior canal gradually thickened with age, reaching adult levels by age 3 years. Further supporting the theory of a congenital/developmental origin for the anatomic defect of SCD is a study by DeJong and colleagues [9] demonstrating significantly less temporal bone volume among SCD patients compared to controls.

Roberto et al. [10] used tetracycline staining to investigate the deposition of the bone in the dog model at 10, 25, and 50 days of age. This study demonstrated progressive deposition of endochondral and endosteal bone at the superior semicircular canal postnatally. The bone deposition decreased with age. These findings are in agreement with the observations in the study by Carey et al. In a related study, Hirvonen and colleagues [11] reported a CT study of the thickness of the superior canal in a group of patients with SCD and those without SCD. Among those with SCD, the contralateral superior canal bone was thinner (or dehiscent), compared to those patients without SCD. This finding supports the notion of SCD as arising from a bilateral process which may be represented in the form of intracranial hypertension or developmental anomaly related to bony deposition in early life.

Several observations may point to an SCD as a developmental anomaly with a "second event" required to produce symptoms. Among these observations are:

1. The above studies demonstrating the development of the bone over the superior semicircular canal occurring later (postnatally) than other parts of the inner ear.
2. The clinical observation of the presence of asymptomatic SCD noted during intraoperative exploration of the middle cranial fossa for encephalocele repair (Fig. 16.3).
3. Symptoms from SCD rarely present in the pediatric population, in spite of a higher incidence of the anatomic dehiscence in children than among adult patients.

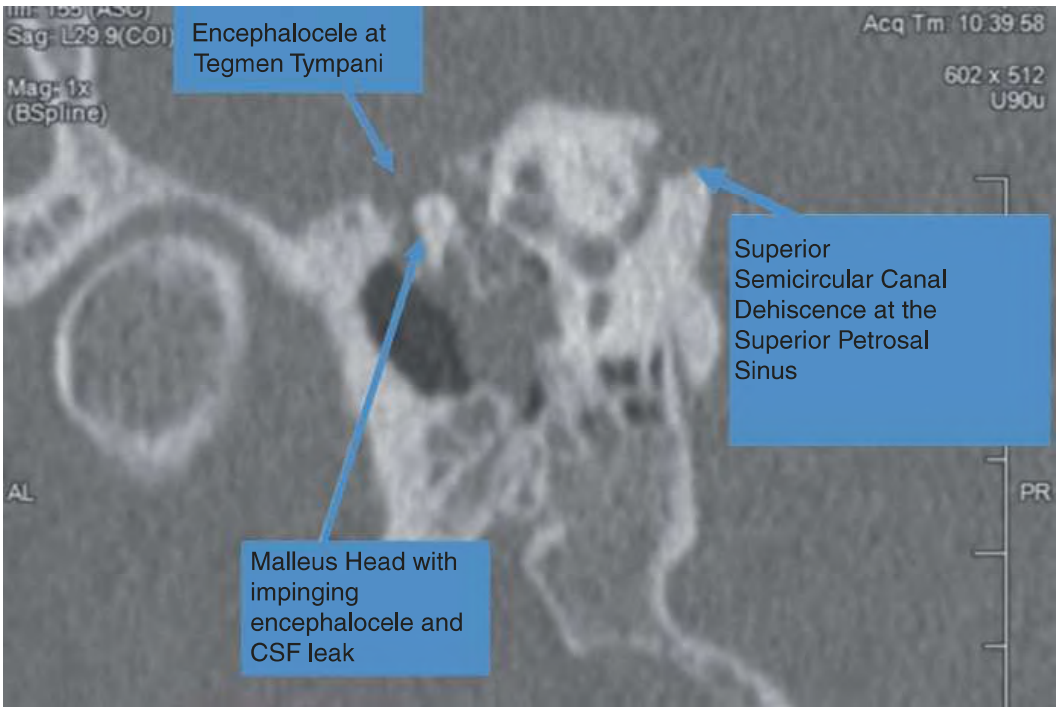

Fig. 16.3 CT scan demonstrating an encephalocele in a patient with an asymptomatic SCD

These observations support the notion that a second event is required in addition to the congenital anomaly of thin or absent superior canal bone in order to produce clinical symptoms. Roughly 25–50% of patients report an event they attribute to symptom onset for SCD [12, 13]. This "second event" is typically noted to be either head trauma, a Valsalva-type episode, or some other type of pressure-altering event that affects either middle ear or intracranial pressure.

Case 1

In 1998 (shortly after we started treating SCD), an 8-year-old female was referred to the author for tympanomastoidectomy for left chronic suppurative otitis media and suspicion of cholesteatoma. A preoperative CT scan demonstrated right SCD. She had no complaints of vertigo/dizziness, autophony, or Tullio's phenomenon and specifically denied these complaints upon questioning. No vestibular evaluation was performed because she was asymptomatic, and no surgical treatment was directed toward the right SCD at that time. She underwent successful left tympanomastoidectomy and was lost to follow-up.

In 2010, she returned to see the authors because of the new onset of right pulsatile tinnitus, episodic vertigo, dizziness, and near constant unsteadiness. The vertigo spells were provoked by straining. Work-up revealed an abnormal right cVEMP and an abnormal right fistula (pressure) test. MRI scan was normal, and a CT scan performed at that time reconfirmed the right SCD.

Comment: This case illustrates three important points: (1) SCD can be asymptomatic, and the authors would argue that almost all symptomatic SCD patients are asymptomatic initially. (2) Most pediatric SCD patients are asymptomatic. (3) This case supports the notion that SCD is congenital/developmental with symptoms acquired later in life.

Clinical Presentation

SCD was first reported by Minor et al. [1] in eight patients who exhibited the symptoms of short-lived vertigo spells in response to certain sounds or activities that would cause transient increases in intracranial or middle ear pressure (Valsalva, coughing, sneezing, nose-blowing, autoinsufflations). These activities would produce a torsional nystagmus, which directly implicated stimulation of the superior semicircular canal. Activities causing increased middle ear pressure (sound, positive pressure in the ear canal, autoinsufflations) induce nystagmus with the slow phase upward and the superior pole of the eye directed *away* from the affected ear. Activities causing a transient elevation in intracranial pressure (Valsalva against a closed glottis, jugular venous compression) or negative pressure in the ear canal resulted in the slow phase of nystagmus directed downward and the superior pole of the eye torqueing *toward* the affected ear. The clinical findings of Tullio's phenomenon and pressure-induced nystagmus associated with SCD have been termed

Minor's syndrome. Although the vertigo caused by SCD is most characteristically reported as short-lived, other characterizations of vestibular symptoms have been reported as well, including more prolonged vertigo spells, chronic disequilibrium, and even possible rare drop attacks [14].

In the second publication [15] on SCD in 1999, we reported the next three SCD patients who had very disparate symptoms. One patient was asymptomatic and had middle fossa exploration to repair an encephalocele. Another patient had "symptoms that mimicked" Meniere's syndrome that resolved with SCD resurfacing. The last patient had symptoms of straining-induced and positional vertigo which was also resolved with resurfacing. Since these first reports of SCD, other variations on clinical presentations have been identified. In a review of their experience with SCD, Zhou et al. [2] described SCD as the "great otologic mimicker" because of the variety of presentations and the variety of other diagnoses from which SCD can be confused.

Case 2

A 74-year-old male was referred after a fall from a ladder 2 years prior. The head injury resulted in an intracranial bleed and a prolonged hospital stay. After regaining consciousness, he began to note left hearing loss, Tullio's phenomenon, autophony, chronic imbalance, and strain-induced vertigo spells. None of these symptoms had been present prior to the head trauma. Audiometry demonstrated left low-frequency mixed hearing loss with a large conductive component and intact acoustic reflexes. Fistula (pressure) test, Valsalva test, and cVEMP were abnormal on the left side. MRI scan demonstrated no CP angle, IAC, or brainstem pathology. CT scan demonstrated a very large left SCD and a much smaller right SCD. Left SCD repair alleviated his symptoms.

Comment: This case illustrates a "classic" presentation of SCD with an obvious second event (the head injury) as the provocateur of the onset of symptoms. The very large left SCD noted on CT scan was almost certainly present prior to the head injury but was asymptomatic before then.

Although the presentation for SCD can be varied, the most recognizable presentation will include Tullio's phenomenon, pressure-induced vertigo (transient increases in intracranial or middle ear pressure), and autophony. While these are the most characteristic presentation of SCD, they are certainly not present in all SCD patients, and their absence cannot be used as a means to exclude the diagnosis of SCD. The more nonspecific symptoms of a vestibulopathy such as head movement-induced disequilibrium are much more common, but not particularly helpful in making the diagnosis of SCD. Pressure and aural fullness are common. Complaints of hearing loss, distorted hearing, and hyper-acute hearing are also common. SCD patients may have been given a variety of other diagnoses prior to presenting in the office. The biggest tip off to a misdiagnosis is nonresponse to prior treatments. This should always prompt the clinician to reassess the prior diagnosis.

Vague cognitive and neurobehavioral symptoms are also frequently reported by SCD patients. While these have been reported in SCD patients, they are not specific to SCD patients and can be seen in other chronic vestibular syndromes such as

potentially comorbid vestibular migraine. These include depression, "brain fog," short-term memory problems, and difficulty with concentration. These symptoms have been documented as present and improved after surgical repair of SCD by Wackym et al. [16].

Physical Exam

Routine head and neck exam in addition to microscopic otoscopy is typically normal in the SCD patient. The vestibular component of the physical exam should include evaluation with infrared video goggles. This may be unremarkable but, if there has been any vestibular loss, may reveal spontaneous nystagmus and head thrust or headshake abnormalities. In some extreme cases, one can identify a spontaneous torsional nystagmus that is synchronous with the pulse. Tuning fork testing in locations (such as the malleolus) not normally used to stimulate the ear can sometimes show positive results in SCD patients.

Testing

Much of the literature discusses vestibular evoked myogenic potentials (VEMP) and high-resolution CT scan as the extent of testing for SCD. While the CT scan is imperative and the VEMP is often helpful, we feel this limited testing is inadequate for patients presenting with SCD. Since SCD is a disorder that can mimic many other otologic disorders, can cause many secondary pathologies, and may require invasive surgery to resolve, we feel a full audiovestibular test battery is warranted.

CT scan slices should be performed at the submillimeter level, preferably 0.24 mm thickness but not thicker than 0.6 mm. The thinner slice scan gives a more accurate portrayal of the defect. Thicker scans are prone to high levels of inaccuracy [17]. MRI should be performed to evaluate for concomitant intracranial abnormalities but not for confirmation of SCD. One of the more frequent finding in SCD patients is Chiari Malformation [18]. Additionally, MRI findings suggestive of elevated intracranial pressure should be sought (i.e., empty sella, vertical tortuosity of the optic nerves, prominent arachnoid spaces around the optic nerves, flattening of the globe, slit-like ventricles, venous sinus abnormalities, Chiari/cerebellar ectopia). MRI, however, is used by some postoperatively to determine whether surgical occlusion of the SSC has been successful.

Audiometric testing may be normal, show some degree of sensorineural hearing loss in the affected ear, or, more characteristically, demonstrate a low-frequency conductive loss (or, more appropriately, bone scores at suprathreshold levels). To distinguish the low-frequency conductive loss patient who has SCD from an otosclerotic patient or other patient with middle ear pathology, impedance testing is warranted. The SCD patient should typically have a normal tympanogram and intact

acoustic reflexes, whereas the patients with otosclerosis will show absent acoustic reflexes [19].

Case 3

A 45-year-old female was diagnosed with otosclerosis and underwent middle ear exploration. No stapes fixation was noted at the time of surgery. She was referred for further evaluation. The patient reported a progressive hearing loss and no significant vestibular symptoms. The patient, however, did report autophony to heartbeat, voice, and eye movement. The audiogram demonstrated a low-frequency conductive loss with elevated bone scores, but acoustic reflexes were normal. Further testing demonstrated that cVEMP was abnormal, as was fistula (pressure) test. MRI scan was unremarkable, and CT scan demonstrated a large SCD.

Comment: This case illustrates another variation for SCD presentation, principally hearing loss mimicking otosclerosis and lacking vestibular symptoms. Clinicians should maintain a high index of suspicion and evaluate prospective stapedectomy patients with acoustic reflex testing. An otosclerotic patient should have absent reflexes, while an SCD patient usually has intact acoustic reflexes.

VEMP, both cervical and ocular, may show reduced threshold responses compared to lab norms, may show an asymmetric result in unilateral cases, or may be completely normal. Additionally, elevation of the amplitude of response has also been suggested as an indication of SSCD, particularly in ocular VEMP. In cases with vestibular loss, the VEMP response may be absent [2]. Electrocochleography is frequently abnormal in SCD patients, which will often normalize after successful surgery [20].

The authors feel a full vestibular evaluation should also be performed on anyone who is to undergo SCD surgery. Abnormalities identified are helpful in the consultation of (1) whether to proceed with surgery, (2) outcome expectations, and (3) documentation of vestibular status akin to preoperative audiometry. Patients with SCD have varied vestibular test profiles including the possibilities of severe unilateral vestibular hypofunction and occasionally severe bilateral vestibular hypofunction. In this setting, successful surgical treatment of SCD will result in continued vestibular symptoms from these deficits. Additionally, BPPV is a frequent secondary pathology that may need treatment along with SCD.

Case 4

A 31-year-old male was referred for evaluation of suspected bilateral SCD. His chief complaint was constant imbalance/oscillopsia punctuated by short-lived spells of rotary vertigo induced by certain sounds and straining. He particularly had trouble with balance in the dark. Prior work-up included an audiogram demonstrating a symmetric high-frequency sensorineural loss beyond 6 kHz, CT scan demonstrating SCD bilaterally, and cVEMP within normal threshold stimulation and normal amplitudes on the left side with an absent response on the right side. No other vestibular evaluation had been performed.

Vestibular evaluation at our office demonstrated electrocochleography, Valsalva testing, fistula testing, and Tullio's testing that were all abnormal and strongly suggestive of SCD. However, there was also significant bilateral caloric weakness,

severely reduced gains on rotary chair, and high-frequency VOR testing indicating significant loss of vestibular function bilaterally. Further, on posturography, the patient would free-fall on SOT 5 and 6.

Comment: The limited test battery of CT scan, audiometry, and VEMP did not completely describe this patient's pathology and missed important information – bilateral vestibular loss. The more extensive testing clearly explains why VEMP testing was not typical of SCD patients (i.e., reduced threshold response or large amplitude response). When there is global vestibular loss, we should expect a reduced or absent VEMP response as in this case. Knowing the severe bilateral loss allows the clinician to better counsel the patient on expectations if surgery is performed. In this case, surgery could resolve Tullio's phenomenon and the strain-induced vertigo spells but is unlikely to improve his chronic disequilibrium to any measurable degree since his bilateral vestibular loss will persist. Without preoperative testing, postoperative vestibular weakness will likely be attributed to the surgical intervention exposing the surgeon to the possibility of litigation.

Video head impulse testing (VHIT) has been introduced to several labs recently. However, because clinical experience with this testing technology has not yet been widespread and has only been available for a limited time, we recommend caution when using this as a means to determine "normal" semicircular canal function. Recent studies have shown poor correlation of VHIT with caloric irrigation studies [21]. Due to this we cannot recommend using this in place of caloric irrigation. However, in the context of SCD, VHIT may prove to be invaluable in determining superior canal function preoperatively and postoperatively. In patients who have undergone SCD occlusion, VHIT may be helpful in determining whether the posterior semicircular canal has also been occluded.

Pathophysiology

The most commonly espoused theory for the pathophysiology of SCD is the "third mobile window theory." This theory posits that the flexible nature of the SCD allows for egress of endolymph in/out of the superior canal resulting in abnormal stimulation of the superior canal cupula. Additionally, low-frequency sound energy transmitted through the inner ear is allowed to dissipate through this bony defect resulting in the conductive gap noted in some SCD patients. Merchant and Rosowski [22] proposed that SCD could be classified among a number of lesions that produce a third mobile window on the scala vestibuli side of the cochlea. Included among these are lateral or posterior canal dehiscence, enlarged vestibular aqueduct, dehiscence of the internal auditory canal, carotid dehiscence (into the cochlea), diffuse dehiscence (such as in Paget's disease), and other congenital anomalies of the inner ear. The hearing loss in these pathologic third mobile window cases exhibits poor air conduction thresholds and good bone conduction thresholds.

However, the third mobile window theory does not completely explain all of the clinical findings of SCD. Certain situations still elude explanation. These include

the presentation of SCD patients with only auditory and no vestibular findings or vice versa, Ménière's-type vertigo spells (prolonged vertigo lasting several hours) [15], and SCD symptoms in patients who have "near dehiscence" (i.e., thin bone without dehiscence).

Gianoli and Soileau [23] proposed the theory that alteration of intracranial pressure may result in increased compliance at the round and oval windows and, if pressure changes were extreme, potential disruption of the windows resulting in a frank middle ear perilymph fistula. This theory could explain the above exceptions to the third mobile window theory and why a second event of head trauma or pressure-altering event frequently brings on symptoms. It also explains why round window reinforcement has been noted in some patients to resolve SCD symptoms (at least temporarily). Gianoli and Soileau further proposed a staging system for SCD which can be referenced in separate article [26].

Other Dehiscences

Among patients who present with symptoms and testing consistent with SCD, there are some who do not have SCD. These patients may be found to have dehiscence of labyrinthine bone in other areas. Among these are posterior semicircular canal dehiscence at the posterior fossa dura or at the jugular bulb, horizontal canal dehiscence (usually due to erosive processes such as cholesteatoma), cochlear dehiscence at the labyrinthine segment of the facial nerve (Fig. 16.4), cochlear dehiscence at the

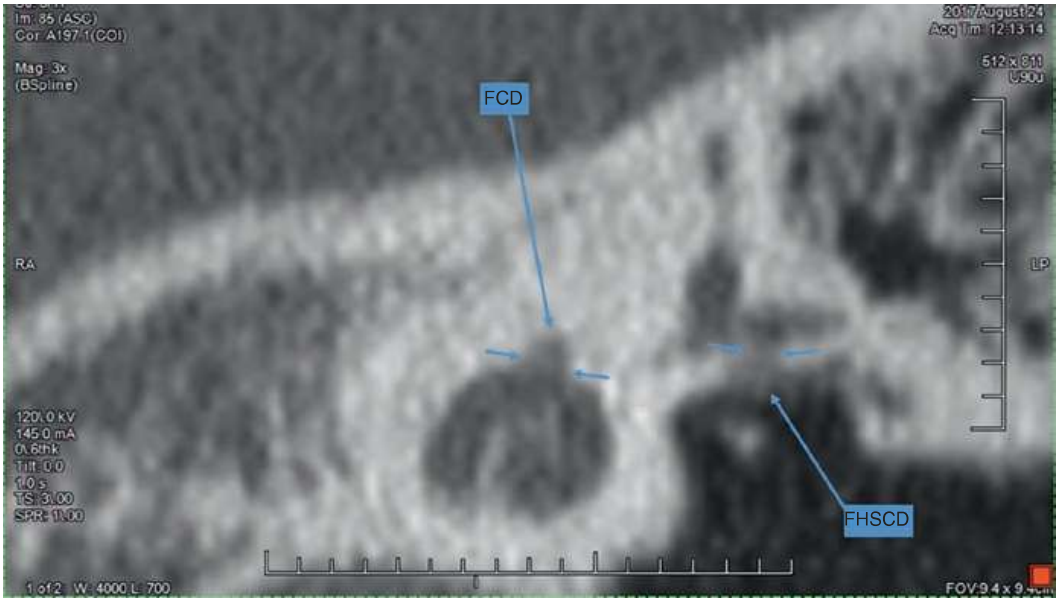

Fig. 16.4 CT scan demonstrating dehiscence of the cochlea at the region of the labyrinthine segment of the facial canal (FCD) and suspicious for dehiscence of the horizontal semicircular canal at the tympanic segment of the facial canal (FHSCD)

carotid artery, and horizontal canal dehiscence near the second genu of the facial nerve (Fig. 16.4). Each of these has minor variations from the typical presentation of SCD, but the most common uniting symptom seems to be pressure-induced dizziness/vertigo from either internal or external sources, although some may have autophony and Tullio's phenomenon. These dehiscences are more commonly found among SCD patients and may be clinically identical in their presentation. Finally, patients may present with a syndrome identical to SCD but have no radiographically visible dehiscence. The collection of patients presenting with this syndrome has been named otic capsule dehiscence syndrome by Wackym et al. [24]

Case 5
A 23-year-old male was referred for vertigo, dizziness, and unilateral hearing loss after being struck by an industrial cable the previous year. The patient also had concomitant facial fractures and closed head injury. The patient reported that the vertigo was provoked by straining and possibly sound. He also noted autophony to heartbeat and voice. Evaluation demonstrated an abnormal cVEMP, fistula (pressure) test, and Valsalva test. MRI scan demonstrated no CPA, IAC, or brainstem pathology. CT scan demonstrated a posterior semicircular canal dehiscence at the junction of a high-riding jugular bulb. Surgical decompression of the jugular bulb with repair of the dehiscence resolved the patient's symptoms.

Comment: Many patients will present with SCD symptoms that do not have SCD. The clinician should look for other defects of the labyrinth which could possibly explain the symptomatology.

Near Dehiscence

Many clinicians have noted patients with SCD symptoms and no bony defect of the SSC or any other place in the labyrinthine bone. Some of these patients will have extreme thinning of the SSC bone to the point where the bone itself is flexible enough to transmit pressure to the inner ear. These so-called near dehiscences share many features but typically do not have reduced thresholds on VEMP testing. They also have a generally favorable outcome with SCD surgery [25].

Tegmen Dehiscence and Ossicular Head Impingement

Among the anomalies frequently seen with SCD are multiple dehiscences of the tegmen tympani and tegmen mastoideum as well as dehiscence of the geniculate ganglion [26]. Usually these are of no significance unless there has been dural herniation through the dehiscence resulting in an encephalocele and possible CSF leak. An encephalocele with prolapse onto the ossicular heads can cause a conductive hearing loss and autophony, which can accompany SCD. Similarly, a large tegmen tympani

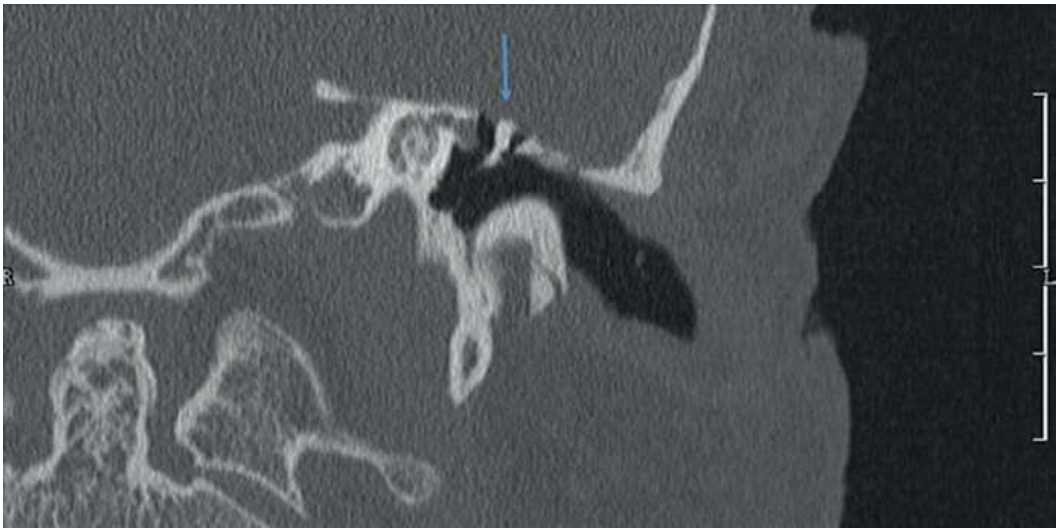

Fig. 16.5 CT scan of an SCD patient with concomitant dehiscence of the tegmen tympani with temporal lobe dura impinging on the ossicular heads (arrow)

dehiscence may allow impingement of the ossicular heads without a prolapsing encephalocele (Fig. 16.5). If SCD repair does not include repair of this type defect, some residual symptoms of autophony and conductive loss are sure to persist.

Conclusions

We continue to learn about SCD and its implications since its first description in the literature 20 years ago. The pathophysiology is likely due to a combination of a third mobile window, increased round/oval window compliance, and concomitant intermittent PLF likely due to fluctuations in middle ear and/or intracranial pressure. The diagnosis of SCD requires a high degree of suspicion due to its varying presentation but must include (1) symptoms consistent with SCD, (2) physiologic testing consistent with SCD, and (3) high-resolution CT scan demonstrating SCD. None of these three elements are sufficient alone. Lastly, a comprehensive audiovestibular test battery is warranted for appropriate management of these complex patients.

References

1. Minor LB, Solomon D, Zinreich JS, Zee DS. Sound- and/or pressure-induced vertigo due to bone dehiscence of the superior semicircular canal. Arch Otolaryngol Head Neck Surg. 1998;124:249–58.
2. Zhou G, Gopen Q, Poe DS. Clinical and diagnostic characterization of canal dehiscence syndrome: a great otologic mimicker. Otol Neurotol. 2007;28(7):920–6.
3. Bom Braga GP, Noble JH, Gebrim EMMS, Labadie RF, Bento RF. The influence of the subarcuate artery in the superior semicircular canal dehiscence and its frequency on stillbirths: illustrative cases and systematic review. Acta Otolaryngol. 2017;22:1–6.

4. Meiklejohn DA, Corrales CE, Boldt BM, Sharon JD, Yeom KW, Carey JP, Blevins NH. Pediatric semicircular canal dehiscence: radiographic and histologic prevalence, with clinical correlation. Otol Neurotol. 2015;36(8):1383–9.
5. Sugihara EM, Babu SC, Kitsko DJ, Haupert HS, Thottam PJ. Incidence of pediatric superior semicircular canal dehiscence and inner ear anomalies: a large multicenter review. Otol Neurotol. 2016;37:1370–5.
6. Carey JP, Minor LB, Nager GT. Dehiscence or thinning of the bone overlying the superior semicircular canal in a temporal bone survey. Arch Otolaryngol Head Neck Surg. 2000;126(2):137–47.
7. Davey S, Kelly-Morland C, Phillips JS, Nunney I, Pawaroo D. Assessment of superior semicircular canal thickness with advancing age. Laryngoscope. 2015;125(8):1940–5.
8. Noonan KY, Russo J, Shen J, Rehm H, Halbach S, Hopp E, Noon S, Hoover J, Eskey C, Sunders J. CDH23 related hearing loss: a new genetic risk factor for semicircular canal dehiscence? Otol Neurotol. 2016;37(10):1583–8.
9. de Jong MA, Carpenter DJ, Kaylie DM, Piker EG, Frank-Ito DO. Temporal bone anatomy characteristics in superior semicircular canal dehiscence. J Otol. 2017;12(4):185–91.
10. Roberto M, Favia A, Lozupone E. Postnatal bone growth in the semicircular canals of the dog. Ital J Anat Embryol. 1998;103:27–34.
11. Hirvonen TP, Weg N, Zinreich SJ, Minor LB. High-resolution CT findings suggest a developmental abnormality underlying superior canal dehiscence syndrome. Acta Otolaryngol. 2003;123(4):477–81.
12. Minor LB. Clinical manifestations of superior semicircular canal dehiscence. Laryngoscope. 2005;115:1717–27.
13. Gianoli G. Unpublished data, 2018.
14. Brantber K, Ishiyama A, Baloh RW. Drop attacks secondary to superior canal dehiscence syndrome. Neurology. 2005;64:2126–8.
15. Smullen JL, Andrist EC, Gianoli GJ. Superior semicircular canal dehiscence: a new cause of vertigo. J La State Med Soc. 1999;151:397–400.
16. Wackym PA, Balaban CD, Mackay HT, Wood SJ, Lundell CJ, Carter DM, Siker DA. Longitudinal cognitive and neurobehavioral functional outcomes before and after repairing otic capsule dehiscence. Otol Neurotol. 2016;37(1):70–82.
17. Tavassolie TS, Penninger RT, Zuñiga MG, Minor LB, Carey JP. Multislice computed tomography in the diagnosis of superior canal dehiscence: how much error, and how to minimize it? Otol Neurotol. 2012;33(2):215–22.
18. Kuhn JJ, Clenney T. The association between semicircular canal dehiscence and Chiari type I malformation. Arch Otolaryngol Head Neck Surg. 2010;136(10):1009–14.
19. Picavet V, Govaere E, Forton G. Superior semicircular canal dehiscence: prevalence in a population with clinical suspected otosclerosis-type hearing loss. B-ENT. 2009;5(2):83–8.
20. Arts HA, Adams ME, Telian SA, El-Kashlan H, Kileny PR. Reversible electrocochleographic abnormalities in superior canal dehiscence. Otol Neurotol. 2009;30(1):79–86.
21. Jung J, Suh MJ, Kim SH. Discrepancies between video head impulse and caloric test in patients with enlarged vestibular aqueduct. Laryngoscope. 2017;127(4):921–6.
22. Merchant SN, Rosowski JJ. Conductive hearing loss caused by third window lesions of the inner ear. Otol Neurotol. 2008;29:282–9.
23. Gianoli G. Superior semicircular canal dehiscence repair. In Babu S, Practical otology for the otolaryngologist. Plural Publishing. San Diego. 2013, 287–296.
24. Wackym PA, Wood SJ, Siker DA, Carter DM. Otic capsule dehiscence syndrome: superior semicircular canal dehiscence syndrome with no radiographically visible dehiscence. Ear Nose Throat J. 2015;94(8):E8–E24.
25. Ward BK, Wenzel A, Ritzl EK, Gutierrez-Hernandez S, Della Santina CC, Minor LB, Carey JP. Near-dehiscence: clinical findings in patients with thin bone over the superior semicircular canal. Otol Neurotol. 2013;34(8):1421–8.
26. Gianoli GJ. Deficiency of the superior semicircular canal. Curr Opin Otolaryngol Head Neck Surg. 2001;9:336–41.